

Hybrid Hyrax Distalizer and Mentoplate for Rapid Palatal Expansion, Class III Treatment, and Upper Molar Distalization

THANH-HA CLARENBACH, DMD
BENEDICT WILMES, DMD, MSD, PhD
BENJAMIN IHSSSEN, DMD
SIVABALAN VASUDAVAN, BDSc, MDSc, MPH
DIETER DRESCHER, DMD, PhD

The prevalence of skeletal Class III malocclusion is estimated at only 3-5% in the Caucasian population¹⁻⁴ and as much as 14% in Chinese and Japanese populations.⁵ Despite the relatively low incidence in Caucasians, about a third of all U.S. orthognathic-surgical patients present with Class III malocclusions.⁶⁻⁸ The etiology may involve a retrognathic maxilla, a prognathic mandible, or both.^{9,10}

A protraction facemask can be used to treat maxillary retrognathia in a preadolescent patient by exerting pressure to separate the circummaxillary sutures and move the maxillary skeletal and dentoalveolar complex forward. When force is applied directly to the maxillary teeth, however, the anchorage loss and anterior movement of the

dentition may lead to anterior crowding and ectopic displacement or impaction of the developing upper canines.¹¹ Anchorage reinforcement by means of ankylosed deciduous canines,¹² dental implants,¹³ or miniplates¹⁴⁻¹⁷ can mitigate these undesirable effects by transferring the orthopedic forces directly to the nasomaxillary complex.

De Clerck described the use of four Bollard miniplates with intermaxillary Class III elastics to treat midface deficiency by orthopedic traction of the maxilla in the late mixed or early adolescent dentition.¹⁸ These bone plates, which have transcutaneous hooks passing through the gingivae, are placed in the infrazygomatic crest of the maxilla and the canine region of the mandible. Surgical



Dr. Clarenbach



Dr. Wilmes



Dr. Ihssen



Dr. Vasudavan



Dr. Drescher

Dr. Clarenbach is a research associate, Dr. Wilmes is a Professor, Dr. Ihssen is a scientific assistant, and Dr. Drescher is a Professor and Head, Department of Orthodontics, University of Düsseldorf, Moorenstrasse 5, 40225 Düsseldorf, Germany. Dr. Vasudavan is an adjunct faculty member, Department of Dentistry, Boston Children's Hospital; a Visiting Lecturer, Department of Developmental Biology, Harvard School of Dental Medicine, Boston; a Senior Research Fellow, Faculty of Science, University of Western Australia, Perth, Australia; and in the private practice of orthodontics in Perth. Dr. Clarenbach is also in the private practice of orthodontics in Wuppertal, Germany; e-mail: clarenbach@klieferorthopaedie-wuppertal.com.

TABLE 1
CEPHALOMETRIC ANALYSIS

	Norm	Pretreatment	Post-Treatment
SNA	82.0°	73.1°	78.1°
SNB	80.3°	75.3°	77.5°
ANB	2.0°	-2.2°	0.7°
Wits appraisal	+1.0mm	-5.5mm	+0.8mm
MP-PP	23.5°	29.4°	24.5°
U1-PP	112.5°	100.5°	113.1°
L1-MP	90.0°	91.1°	87.1°
U1-L1	131.0°	139.0°	135.2°

criteria limit the technique to patients who are older than 10 and have enough bone density in the infrazygomatic crest to retain the fixation screws with minimal chance of loosening. The lower canines also need to be sufficiently erupted for safe placement of the plates close to the inferior border of the mandible.

Technique

Protraction facemask therapy is often combined with rapid palatal expansion to enhance sagittal advancement of the maxilla.^{19,20} The skeletally anchored Hybrid Hyrax* appliance, introduced by Wilmes and colleagues, requires a minimally invasive surgical procedure. Two mini-implants are inserted in the paramedian area of the anterior hard palate to support anchorage in the sagittal and transverse dimensions.²¹⁻²⁶ Thick lateral soft tissue limits the distance between the mini-implants to 5-10mm. When positioned in a paramedian pattern, the mini-implants should not be angulated anteriorly, but should instead be placed directly perpendicular to the occlusal plane. The relatively low volume of bone in this region requires the use of a shorter mini-implant, 7-9mm in length.

Wilmes and colleagues also developed the titanium Mentoplate, an appliance surgically positioned inferior to the lower incisors.²¹ The advan-

tage of the Mentoplate over Bollard fixation plates is that it can be used in younger Class III patients. Although it is similar to a facemask in requiring patient compliance, it is presumed to encourage better acceptance because the elastics are intraoral rather than extraoral. Combining the Hybrid Hyrax in the maxilla and the Mentoplate in the anterior mandible facilitates transfer of the protractive forces directly to the underlying skeletal structures. In addition, a modification called the Hybrid Hyrax Distalizer provides upper-molar distalization during orthopedic advancement of the maxilla.²⁷

Case Report

An 11-year-old female presented with an anterior crossbite, a severe Class III malocclusion, a 9mm maxillary transverse deficiency, and about 4mm of mesial migration of the upper premolars and first molars, resulting in bilateral ectopic upper canines and lower incisor malalignment. Clinical examination revealed an anterior functional shift with a centric relation-centric occlusion discrepancy of 4mm (Fig. 1). The upper incisors were retroclined; the molar relationships were Class III on both sides, with a Class III canine relationship on the right and a Class I canine relationship on the left. The patient had a -4mm overjet, a 5mm overbite, and coincident maxillary and mandibular dental midlines. Her facial features were leptopro-
sopic, but she had a straight profile (Table 1).

*Registered trademark of Dentaaurum, Inc., Newtown, PA; www.dentaaurum.com.

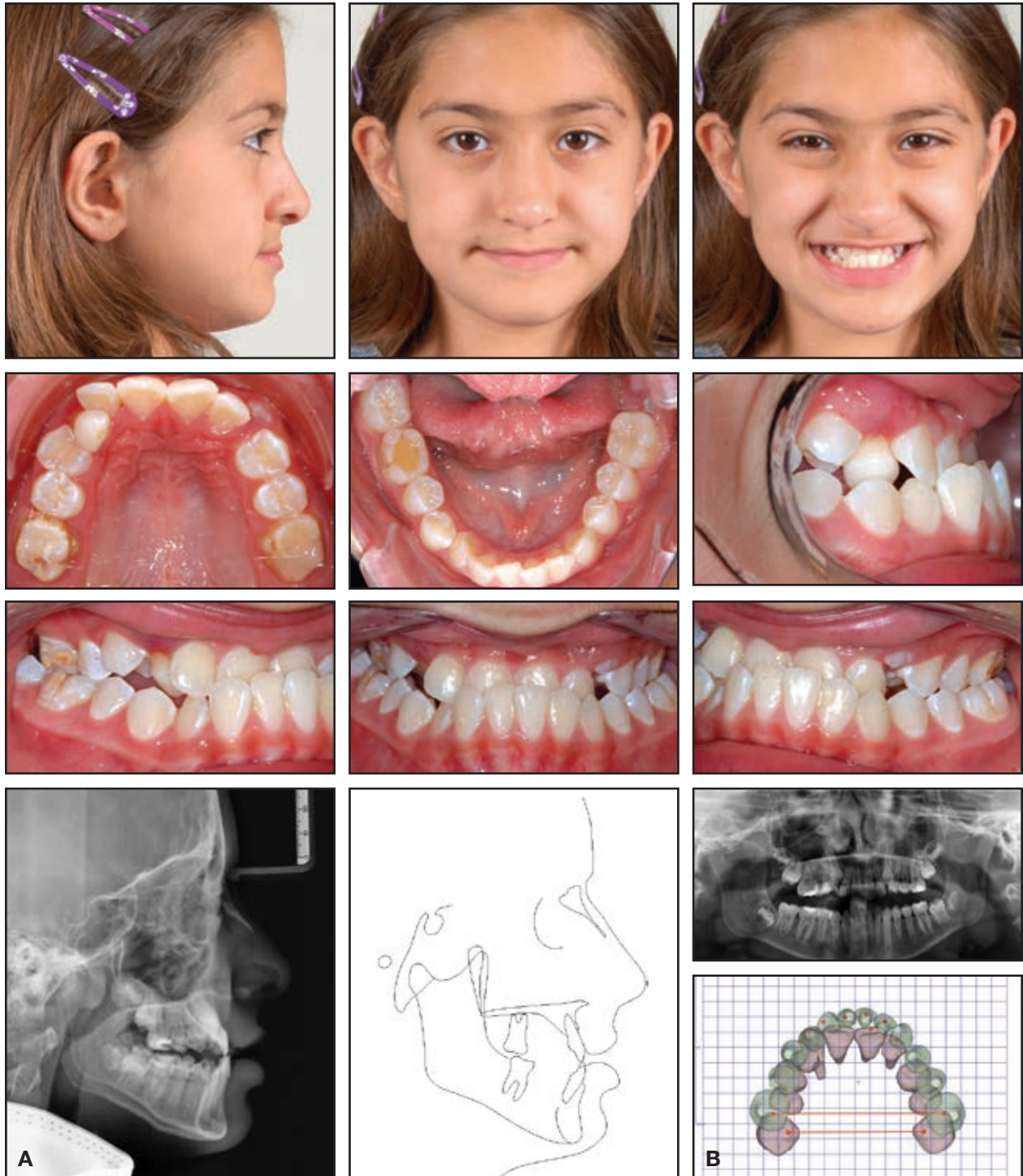


Fig. 1 A. 11-year-old female Class III patient with anterior crossbite before treatment. B. Superimposition of dental arches (1 square = 4mm).

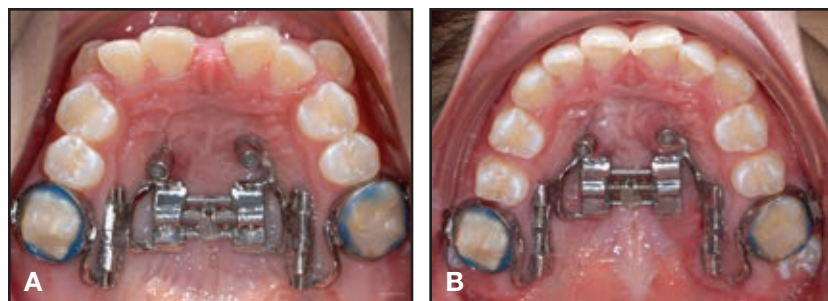


Fig. 2 A. After 12 days of maxillary expansion with Hybrid Hyrax* Distalizer. **B.** After eight months of molar distalization.

Treatment objectives included eliminating the Class III malocclusion by maxillary protraction, without applying force directly to the teeth; enabling continued development and eruption of the upper canines; leveling and aligning both arches; resolving the lower anterior crowding while avoiding excessive proclination of the incisors; and establishing a Class I relationship with normal and stable overbite and overjet. Removal of the upper first premolars was considered as a way to address the maxillary crowding and insufficient arch length for alignment of the ectopic upper canines. These extractions could have led to extrusion of the anterior segment during retraction and further loss of upper incisor torque, however, which would have undermined our ability to address the sagittal Class III relationships. A second treatment option would have been to use cervical headgear to distalize the maxillary dentition, but this would have had a restrictive effect on the maxilla and conflicted with our objective of maxillary advancement. After the relative merits, shortcomings, and risks of each treatment modality were explained to the patient and her parents, they decided to proceed with the Hybrid Hyrax Distalizer and Mentoplate—primarily due to the simplicity of this approach.²⁸

Following the application of topical and local anesthesia, two Benefit system** 2mm × 9mm mini-implants were inserted adjacent to the mid-palatal suture in a transverse configuration, using a manual contra-angle driver. Stainless steel bands were sized and fitted to the upper first permanent molars. A polyvinyl siloxane impression of the maxilla was taken for fabrication of the Hybrid

Hyrax Distalizer. Under local anesthesia, an oral surgeon reflected a full-thickness mucoperiosteal flap to place the Mentoplate in the anterior mandible using four monocortical screws. The Hybrid Hyrax Distalizer was affixed to the mini-implants and molars with a light-cured cement.***

Expansion was immediately begun by activating the sagittal split screw 90° four times per day, .2mm per turn, for a total of .8mm daily. A calibrated 400g protraction force was applied on each side by attaching intraoral elastics directly to the Mentoplate. After 12 days of continuous activation, the transverse dimension of the maxillary intermolar width had increased by 9mm (Fig. 2A).

The sagittal split screw was then secured for the molar-distalization phase. The patient was instructed to activate the bilateral distalization screws weekly (.2mm per week). After eight months, the molars had been distalized 4mm (Fig. 2B). The patient was instructed to continue wear-

*Registered trademark of Dentaaurum, Inc., Newtown, PA; www.dentaaurum.com.

**PSM Medical Solutions, Tuttlingen, Germany; www.psm.ms. Distributed in the U.S. by PSM North America, Indio, CA; www.psm-na.us.

***Band-Lok, Reliance Orthodontic Products, Itasca, IL; www.relianceorthodontics.com.

†Registered trademark of Ormco Corporation, Orange, CA; www.ormco.com.

‡Registered trademark of Dentsply GAC, Islandia, NY; www.dentsply.com.

††Trademark of Strite Industries Ltd., Cambridge, ON; www.speedsystem.com.

‡‡Rocky Mountain Orthodontics, Denver, CO; www.rmortho.com.

§3M Unitek, Monrovia, CA; www.3MUnitek.com.

ing the intraoral elastics throughout the distalization phase.

The upper incisors were protracted using a 2 × 4 partial fixed appliance with an .016" × .022" TMA† protrusion base arch and an .016" × .022" stainless steel anterior segmental wire (Fig. 3). After five months, progress records were obtained to develop a comprehensive biomechanical plan for full fixed appliances. The lower left central incisor was extracted to address the lower arch-length discrepancy. Edgewise brackets were then bonded to all teeth, and an .014" Sentalloy‡ superelastic nickel titanium archwire was inserted in the upper arch and an .016" SPEED Superelastic‡ coaxial superelastic nickel titanium archwire in the lower arch. The patient was advised to continue wearing the intraoral elastics connected to the Mentoplate. Interceptive treatment to correct the Class III relationship took a total of 19 months, at which point the Mentoplate was surgically removed.

A modified Quad-Helix‡‡ appliance was fabricated to maintain and adjust the transverse width and provide segmental leveling for alignment of the upper second molars. Attachments were bonded to the palatal surfaces of the molars and connected to the modified Quad-Helix appliance with elastomeric chain (Fig. 4). An .016" × .022" Twistflex§ archwire was used for detailing and finishing, in conjunction with triangular elastics in the premolar and canine regions.

The fixed-appliance phase was completed in 13 months. A lower 3-3 lingual retainer was bonded, and a removable Andresen activator was delivered for nighttime wear to prevent relapse of the Class III malocclusion.

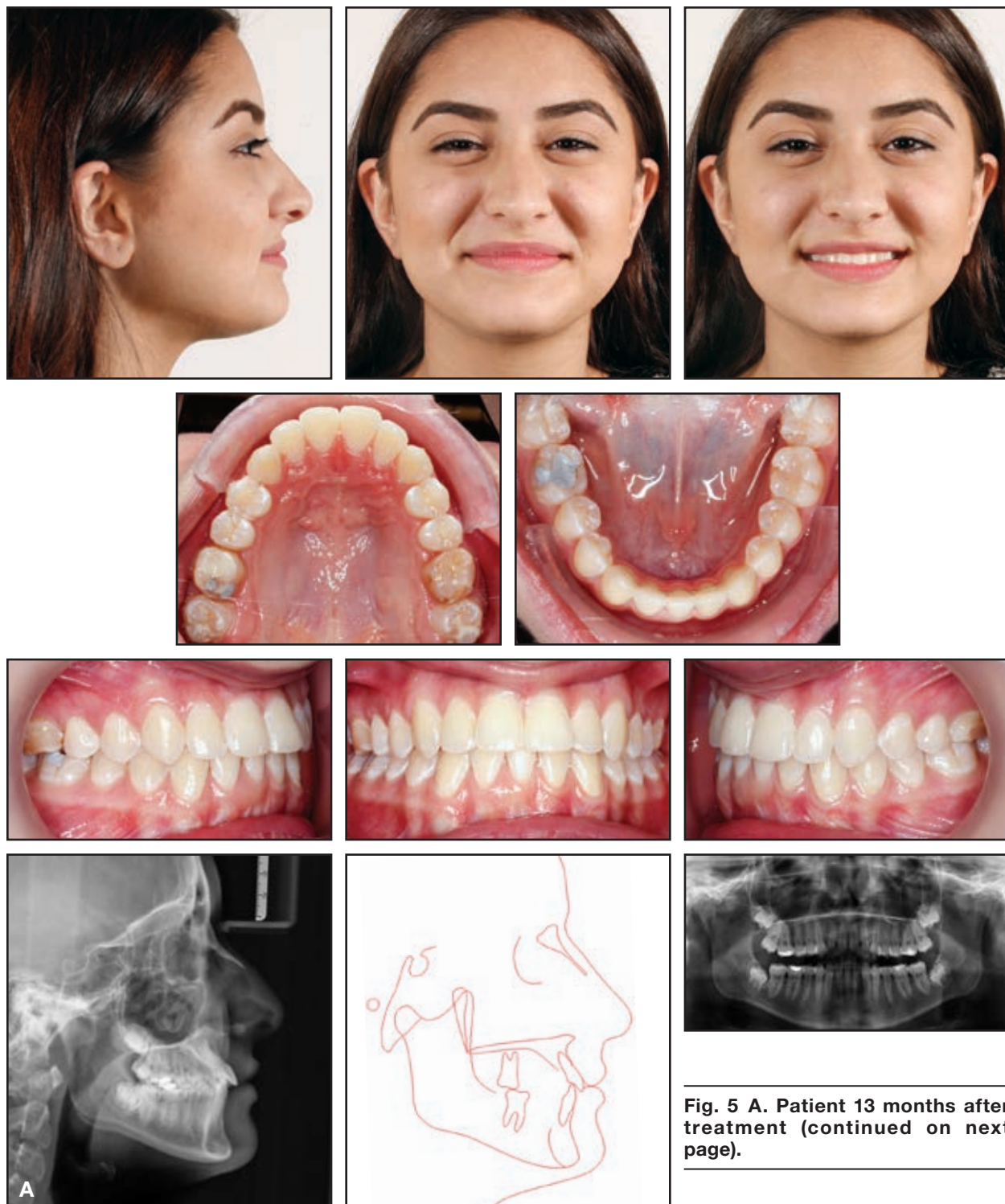
After treatment, the patient had a bilateral Class I relationship with normal overbite and overjet and near-ideal upper and lower incisor angulation. Cephalometric analysis confirmed that the Class III was corrected by maxillary protraction, as indicated by an increase in SNA from 73.1° to

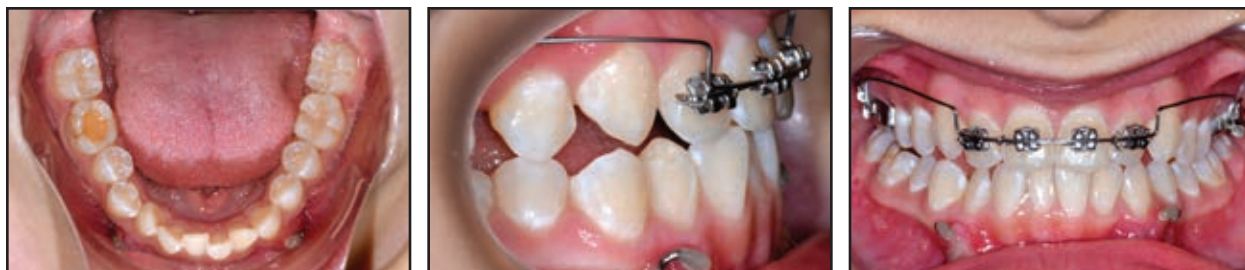

Fig. 3 After five months of upper incisor protraction with 2 × 4 partial fixed appliance, .016" × .022" TMA† protrusion base arch, and .016" × .022" stainless steel anterior segmental wire.

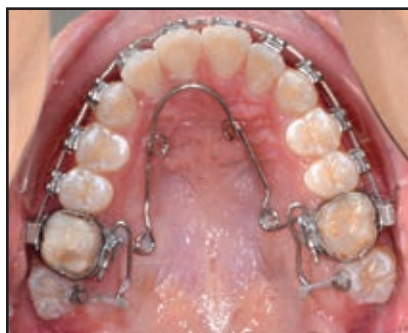

Fig. 4 19 months later, modified Quad-Helix‡‡ placed for segmental alignment of upper second molars.



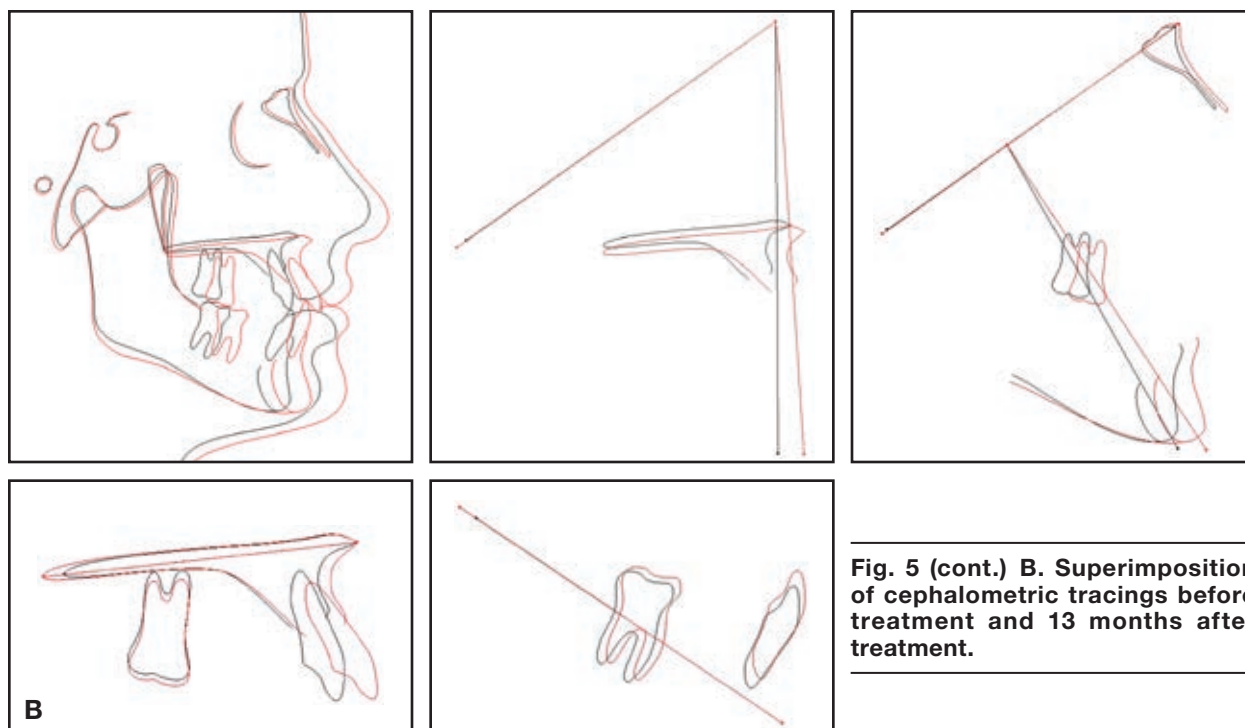


Fig. 5 (cont.) B. Superimposition of cephalometric tracings before treatment and 13 months after treatment.

78.1° (Table 1). The maxillary intermolar dimension was increased by about 9mm. Superimposition showed autorotation of the mandible, with a 4.9° reduction in MP-PP, so that the facial form became more mesoprosopic.

The patient complied with wearing the removable Andresen activator as instructed. A follow-up review 13 months after treatment demonstrated a stable occlusion (Fig. 5).

Discussion

The anterior palate offers a stable insertion site for larger mini-implants because of its high bone quality, thin overlying soft tissue, and negligible risk of interference with teeth or roots.²⁷ One study reported a success rate of 98% for palatal mini-implants.²⁹ Predrilling to a depth of 2-3mm is indicated only in adult patients, due to their greater bone mineralization, but is rarely required in children and young adolescents.

The combination of a Hybrid Hyrax Distalizer and Mentoplate offers several advantages in Class III treatment. It is relatively esthetic because the protraction forces are applied intra-orally. The sagittal forces are transferred directly to the nasomaxillary complex, with no observable anchorage loss as manifested by mesial migration of the maxillary posterior teeth. The transverse forces for rapid maxillary expansion are applied anterior to the mini-implants and thus closer to the center of resistance of the nasomaxillary complex, while the upper molars are distalized with the same appliance.

In our patient, the application of intermaxillary elastics with the Mentoplate resulted in a substantial improvement in the Wits appraisal (6.3mm), more than the reported average of 4.1mm with the Hybrid Hyrax and protraction facemask.³⁰ This improvement was primarily caused by forward movement of the maxilla, as demonstrated by a 5° increase in SNA. Only mild

irritation occurred on the left side of the Mento-plate where the plate extension passed over mobile mucosa.

Treatment duration was considered acceptable in light of the high level of commitment shown by the patient and her family. A randomized clinical trial conducted by Mandall and colleagues found that 70% of the children treated with a protraction facemask retained favorable changes to their maxillary and mandibular bases over three years,³¹ suggesting that such changes are stable. Further studies are required to assess the long-term stability of the Hybrid Hyrax Distalizer in combination with the Mentoplate.

REFERENCES

1. Huber, R.E. and Reynolds, J.W.: A dentofacial study of male students at the University of Michigan in the physical hardening program, *Am. J. Orthod.* 32:1-21, 1946.
2. Humphreys, H.F. and Leighton, B.C.: A survey of antero-posterior abnormalities of the jaws in children between the ages of 2 and 5½ years of age, *Br. Dent. J.* 88:3-15, 1950.
3. Massler, M. and Frankel, J.M.: Prevalence of malocclusion in children aged 14 to 18 years, *Am. J. Orthod.* 37:751-768, 1951.
4. Ngan, P.; Hu, A.M.; and Fields, H.W. Jr.: Treatment of Class III problems begins with differential diagnosis of anterior crossbites, *Pediat. Dent.* 19:386-395, 1997.
5. Irie, M. and Nakamura, S.: Orthopedic approach to severe skeletal Class III malocclusion, *Am. J. Orthod.* 67:377-392, 1975.
6. Proffit, W.R.; Phillips, C.; Dann, C. 4th; and Turvey, T.A.: Stability after surgical-orthodontic correction of skeletal Class III malocclusion, 1. Mandibular setback, *Int. J. Adult Orthod. Orthog. Surg.* 6:7-18, 1991.
7. Proffit, W.R.; Phillips, C.; Prewitt, J.W.; and Turvey, T.A.: Stability after surgical-orthodontic correction of skeletal Class III malocclusion, 2. Maxillary advancement, *Int. J. Adult Orthod. Orthog. Surg.* 6:71-80, 1991.
8. Proffit, W.R.; Phillips, C.; and Turvey, T.A.: Stability after surgical-orthodontic corrective of skeletal Class III malocclusion, 3. Combined maxillary and mandibular procedures, *Int. J. Adult Orthod. Orthog. Surg.* 6:211-225, 1991.
9. Litton, S.F.; Ackermann, L.V.; Isaacson, R.J.; and Shapiro, B.L.: A genetic study of Class 3 malocclusion, *Am. J. Orthod.* 58:565-577, 1970.
10. Proffit, W.R.; Fields, H.W., Jr.; and Moray, L.J.: Prevalence of malocclusion and orthodontic treatment need in the United States: Estimates from the NHANES III survey, *Int. J. Adult Orthod. Orthog. Surg.* 13:97-106, 1998.
11. Williams, M.D.; Sarver, D.M.; Sadowsky, P.L.; and Bradley, E.: Combined rapid maxillary expansion and protraction facemask in the treatment of Class III malocclusions in growing children: A prospective long-term study, *Semin. Orthod.* 3:265-274, 1997.
12. Kokich, V.G.; Shapiro, P.A.; Oswald, R.; Koskinen-Moffett, L.; and Clarren, S.K.: Ankylosed teeth as abutments for maxillary protraction: A case report, *Am. J. Orthod.* 88:303-307, 1985.
13. Henry, P.J.: Clinical experiences with dental implants, *Adv. Dent. Res.* 13:147-152, 1999.
14. Kircelli, B.H. and Pektas, Z.O.: Midfacial protraction with

- skeletally anchored face mask therapy: A novel approach and preliminary results, *Am. J. Orthod.* 133:440-449, 2008.
15. De Clerck, H.; Cevdanes, L.; and Baccetti, T.: Dentofacial effects of bone-anchored maxillary protraction: A controlled study of consecutively treated Class III patients, *Am. J. Orthod.* 138:577-581, 2010.
16. Kaya, D.; Kocadereli, I.; Kan, B.; and Tasar, F.: Effects of facemask treatment anchored with miniplates after alternate rapid maxillary expansions and constrictions: A pilot study, *Angle Orthod.* 81:639-646, 2011.
17. Sar, C.; Arman-Özçirpici, A.; Uçkan, S.; and Yazici, A.C.: Comparative evaluation of maxillary protraction with or without skeletal anchorage, *Am. J. Orthod.* 139:636-649, 2011.
18. De Clerck, H.J.; Cornelis, M.A.; Cevdanes, L.H.; Heymann, G.C.; and Tulloch, C.J.: Orthopedic traction of the maxilla with miniplates: A new perspective for treatment of midface deficiency, *J. Oral Maxillofac. Surg.* 67:2123-2129, 2009.
19. Baccetti, T.; McGill, J.S.; Franchi, L.; McNamara, J.A. Jr.; and Tollaro, I.: Skeletal effects of early treatment of Class III malocclusion with maxillary expansion and face-mask therapy, *Am. J. Orthod.* 113:333-343, 1998.
20. Jäger, A.; Braumann, B.; Kim, C.; and Wahner, S.: Skeletal and dental effects of maxillary protraction in patients with Angle Class III malocclusion: A meta-analysis, *J. Orofac. Orthop.* 62:275-284, 2001.
21. Wilmes, B.; Nienkemper, M.; Ludwig, B.; Kau, C.H.; and Drescher, D.: Early Class III treatment with a hybrid Hyrax-Mentoplate combination, *J. Clin. Orthod.* 45:15-21, 2011.
22. Wilmes, B. and Drescher, D.: A miniscrew system with interchangeable abutments, *J. Clin. Orthod.* 42:574-580, 2008.
23. Wilmes, B.; Drescher, D.; and Nienkemper, M.: A miniplate system for improved stability of skeletal anchorage, *J. Clin. Orthod.* 43:494-501, 2009.
24. Wilmes, B.; Nienkemper, M.; and Drescher, D.: Application and effectiveness of a mini-implant- and tooth-borne rapid palatal expansion device: The Hybrid Hyrax, *World J. Orthod.* 11:323-330, 2010.
25. Wilmes, B.; Bowman, S.J.; and Baumgaertel, S.: Fields of application of mini-implants, in *Mini-Implants in Orthodontics: Innovative Anchorage Concepts*, ed. B. Ludwig, S. Baumgaertel, and S.J. Bowman, Hanover Park, IL, Quintessence Publishing Co., 2008, pp. 91-122.
26. Ludwig, B.; Glasl, B.; Bowman, S.J.; Drescher, D.; and Wilmes, B.: Miniscrew-supported Class III treatment with the Hybrid RPE Advancer, *J. Clin. Orthod.* 44:533-539, 2010.
27. Wilmes, B.; Ludwig, B.; Katyal, V.; Nienkemper, M.; Rein, A.; and Drescher, D.: The Hybrid Hyrax Distalizer, a new all-in-one appliance for rapid palatal expansion, early Class III treatment and upper molar distalization, *J. Orthod.* 41: S47-S53, 2014.
28. Cureton, S.L.; Regennitter, F.J.; and Yancey, J.M.: The role of the headgear calendar in headgear compliance, *Am. J. Orthod.* 104:387-394, 1993.
29. Karagiolidou, A.; Ludwig, B.; Pazera, P.; Gkantidis, N.; Pandis, N.; and Katsaros, C.: Survival of palatal miniscrews used for orthodontic appliance anchorage: A retrospective cohort study, *Am. J. Orthod.* 143:767-772, 2013.
30. Nienkemper, M.; Wilmes, B.; Pauls, A.; and Drescher, D.: Maxillary protraction using a hybrid Hyrax-facemask combination, *Prog. Orthod.* 14:5, 2013.
31. Mandall, N.; Cousley, R.; DiBiase, A.; Dyer, F.; Littlewood, S.; Mattick, R.; Nute, S.; Doherty, B.; Stivaros, N.; McDowall, R.; Shargill, I.; Ahmad, A.; Walsh, T.; and Worthington, H.: Early Class III protraction facemask treatment effective? A multicentre, randomized, controlled trial: 3-year follow-up, *J. Orthod.* 39:176-185, 2012.