

The Easy Driver for Placement of Palatal Mini-Implants and a Maxillary Expander in a Single Appointment

ORONZO DE GABRIELE, DDS, MD
GIANLUCA DALLATANA, DT
ROBERTO RIVA, DT
SIVABALAN VASUDAVAN, BDSc, MDSc, MPH
BENEDICT WILMES, DMD, MSD, PhD

In a preadolescent patient, a Class III malocclusion with maxillary retrognathia is conventionally addressed with a protraction facemask and rapid maxillary expansion. The corollary of this approach, however, is an inevitable mesial migration of the dentition, which results in anterior crowding and may necessitate extraction of the upper first premolars.¹ Mesial molar migration can be mitigated by adding anchorage from intentionally ankylosed teeth,² dental implants,³ or miniplates.⁴⁻⁶ These methods provide the additional advantage of transferring orthopedic forces directly to the nasomaxillary complex.

Wilmes and colleagues have introduced the Hybrid Hyrax* expansion appliance to avoid anchorage loss in such cases.⁷⁻¹⁵ In a minimally invasive procedure, two mini-implants are placed in the paramedian area of the anterior palate to support anchorage in the sagittal and transverse dimensions.¹⁶ The upper permanent or deciduous molars can thus be stabilized in their positions while the maxilla is orthopedically displaced in an anterior direction. The appliance reduces transverse forces on the dentition during maxillary expansion, resulting in less buccal tipping, root dam-

age, and gingival dehiscence.^{8-13,15} Because of these perceived advantages, several groups of authors developed a modified concept of hybrid anchorage for expansion, called micro-implant-assisted rapid palatal expansion (MARPE), using four mini-implants and four anchor teeth.¹⁷⁻¹⁹

Liou and colleagues have described a method to enhance the stimulatory orthopedic effect of

*Forestadent GmbH, Pforzheim, Germany; www.forestadent.com.

**Registered trademark of Uniontech Orthodontic Lab, Parma and Milan, Italy; www.uniontech.it.



Dr. De Gabriele



Mr. Dallatana



Mr. Riva



Dr. Vasudavan



Dr. Wilmes

Dr. De Gabriele is a Visiting Clinical Lecturer at the Second University of Naples, Italy, and in the private practice of orthodontics in Lecce, Italy. Mr. Dallatana and Mr. Riva are dental technicians specializing in digital orthodontics at Uniontech Orthodontic Lab, Parma and Milan, Italy. Dr. Vasudavan is an adjunct faculty member, Department of Dentistry, Boston Children's Hospital; a Visiting Lecturer, Department of Developmental Biology, Harvard School of Dental Medicine, Boston; a Senior Research Fellow, Faculty of Science, University of Western Australia, Perth, Australia; and in the private practice of orthodontics in Perth. Dr. Wilmes is a Professor, Department of Orthodontics, University of Düsseldorf, Düsseldorf, Germany; a Visiting Professor, Department of Orthodontics, University of Alabama at Birmingham School of Dentistry; and the developer of the Benefit system; e-mail: wilmes@med.uni-duesseldorf.de.

maxillary expansion by alternating seven-day periods of expansion and constriction, 1mm per day, over seven to nine weeks (Alt-RAMEC).²⁰⁻²³ To achieve Class III correction, they employed intra-oral springs. Franchi and colleagues combined the Alt-RAMEC protocol with a protraction facemask using the deciduous teeth as anchorage.^{24,25} These sutural expansion/protraction procedures pose a risk of periodontal damage and mesial migration, however, when the forces are only toothborne. To reduce such risk, the Hybrid Hyrax expander, with mini-implants in the anterior hard palate, can be used in conjunction with the Alt-RAMEC protocol. This approach avoids mesial migration of the upper molars when using a facemask and also prevents any tipping, loosening, or periodontal damage of the premolars or deciduous molars while the maxilla is being expanded.²⁶

Orthodontists may not initially feel confident in locating ideal positions for the placement of palatal mini-implants. Additionally, the quantity and quality of available bone in the anterior hard palate varies among patients, especially those with cleft lip or palate. A surgical insertion guide can help overcome these challenges. The present article describes a guide called Easy Driver,** which utilizes digital technology to allow placement of palatal mini-implants and a maxillary expansion appliance during the same appointment.

Easy Driver Protocol

A plaster cast from a silicone impression is laser-scanned to produce a digital stereolithography file, which is superimposed on a cone-beam computed tomography image or a lateral cephalometric radiograph to identify optimal sites for mini-implant placement (Fig. 1). Virtual planning software is used to confirm the precise anatomical positions of the mini-implants in the anterior hard palate (Fig. 2). A rapid-prototyping process produces the Easy

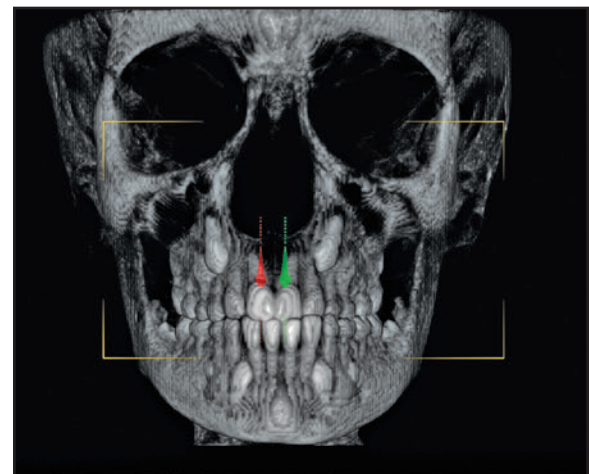


Fig. 1 Palatal mini-implant positions identified using cone-beam computed tomography.

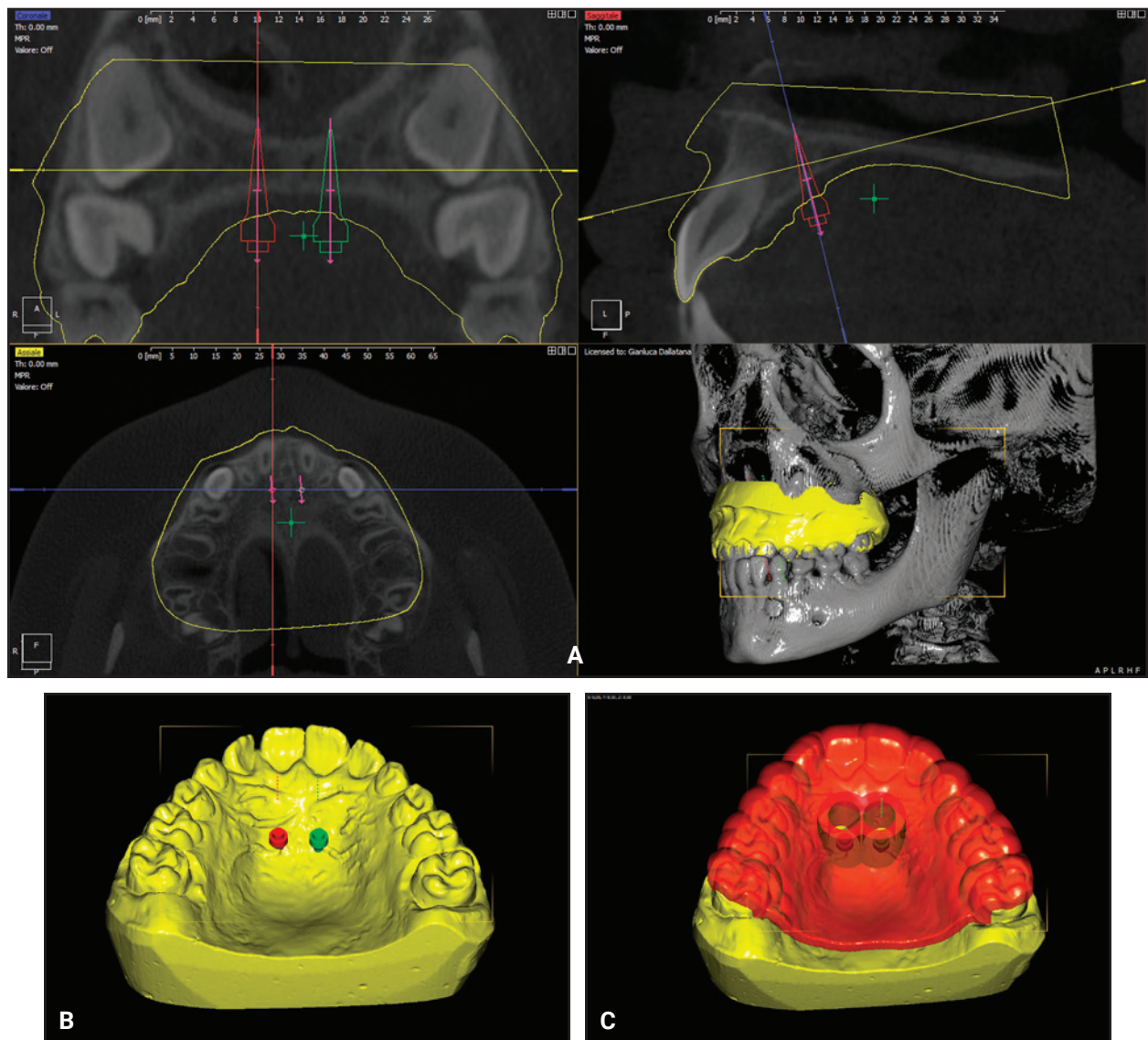


Fig. 2 A. Virtual positioning of mini-implant analogs. B. Digital model with mini-implant analogs. C. Virtual guide used to position mini-implant analogs on plaster cast by dental technician and intraorally by clinician.

Driver surgical insertion guide for precise location of the mini-implants in the mouth (Fig. 3). A Hybrid Hyrax appliance can be fabricated on the same cast. Mini-implants are inserted through the surgical guide using a special contra-angle screwdriver (Fig. 4). This process allows the insertion of both the mini-implants and the Hyrax appliance during the same appointment.

Case Report

An 11-year-old male in the middle mixed dentition presented for treatment of an anterior and left posterior crossbite (Fig. 5). He had a concave facial profile and a retrusive midface. Intra-oral examination showed a Class III malocclusion with half-unit mesial molar and canine relation-

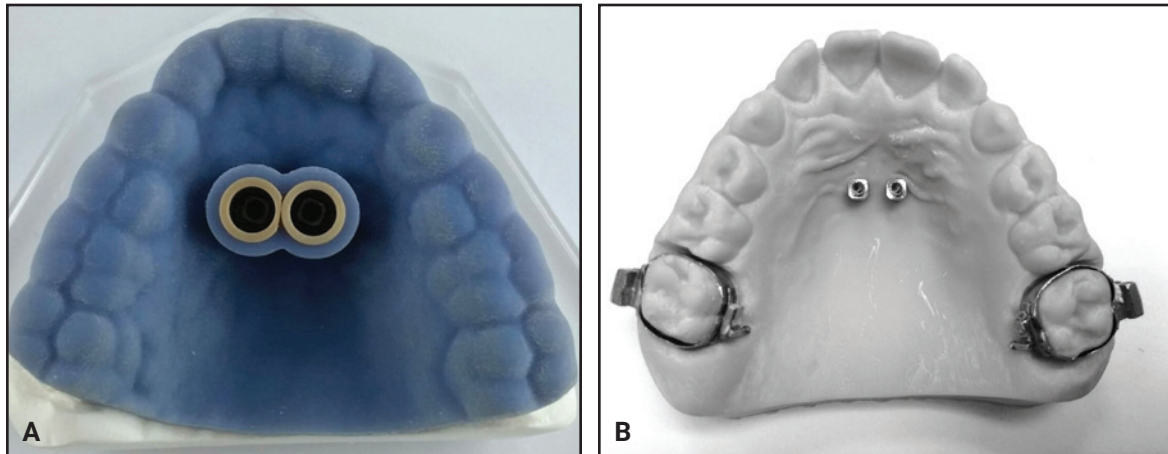


Fig. 3 A. Easy Driver guide on plaster cast. B. Mini-implant analogs on cast.

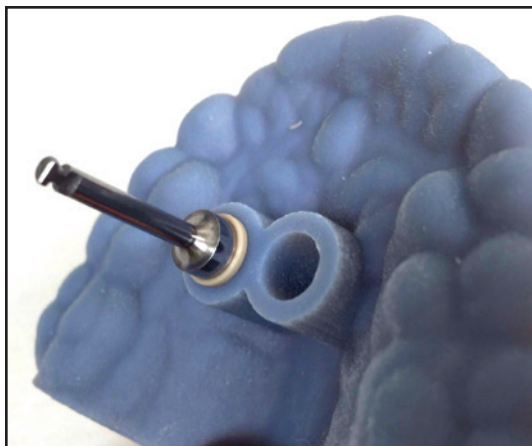


Fig. 4 Contra-angle screwdriver used to insert mini-implants.

ships, a -2mm overjet, a 2mm overbite, and a mandibular midline deviation to the left. A lateral functional shift to the left had been caused by premature occlusal contact, secondary to maxillary transverse constriction. The occlusal trauma had also led to gingival recession on the lower right central incisor.

A panoramic radiograph revealed developing canines, first and second premolars, and second and third molars. Cephalometric analysis (Table 1) indicated a distinct skeletal Class III (Wits appraisal = -5.4mm , ANB = -2°) with a retrognathic maxilla (SNA = 74.9°) and slightly retrognathic

mandible (SNB = 77°). Treatment objectives were to correct the skeletal maxillary deficiency by maxillary protraction, using the modified alt-RA-MEC protocol, and to correct the anterior crossbite.

The patient and parents elected treatment with a protraction facemask rather than intraoral skeletal anchorage using Bollard plates***²⁷ or a Mentoplate†⁸ because of their concerns about a

***Registered trademark of Tita-Link, Brussels, Belgium; www.tita-link.com.

†PSM Medical Solutions, Tuttlingen, Germany; www.psm-na.us. Distributed in the U.S. by Mondeal North America, Inc., Indio, CA; www.mondeal-ortho.com.

TABLE 1
CEPHALOMETRIC ANALYSIS

	Norm	Pretreatment	Post-Treatment	Retention
SNA	$82^{\circ} \pm 3.5^{\circ}$	74.9°	79.3°	78.3°
SNB	$80.9^{\circ} \pm 3.4^{\circ}$	77.0°	77.4°	78.2°
ANB	$1.6^{\circ} \pm 1.5^{\circ}$	-2.0°	1.9°	0.1°
Posterior/anterior facial height (S-Go/N-Me)	$65\% \pm 4.0\%$	62.4%	63.1%	62.3%
Na-S-Go	$67^{\circ} \pm 10.0^{\circ}$	102.5°	102.3°	104.1°
Upper/lower facial height (N-ANS/N-Gn)	$45\% \pm 1.0\%$	43.3%	44.3%	42.3%
Upper facial height (N-ANS)	$50\text{mm} \pm 2.5\text{mm}$	47.8mm	49.6mm	49.3mm
Lower anterior facial height (ANS-Me)	$66\text{mm} \pm 6.0\text{mm}$	60.8mm	60.5mm	65.5mm
Craniomaxillary base/SN-PP	$7.3^{\circ} \pm 3.5^{\circ}$	2.1°	4.2°	2.0°
Palatal-mandibular plane (PP-MP)	$25^{\circ} \pm 6.0^{\circ}$	33.0°	30.1°	33.4°
SN-GoGn	$32.9^{\circ} \pm 5.2^{\circ}$	32.0°	32.7°	32.8°
SN-FOP	$19^{\circ} \pm 4.0^{\circ}$	19.5°	18.6°	18.9°
Gonial angle (Ar-Go-Me)	$126.4^{\circ} \pm 6.7^{\circ}$	122.4°	125.8°	124.4°
U1-SN	$102.3^{\circ} \pm 5.5^{\circ}$	107.1°	104.8°	101.8°
Mandibular unit length (Co-Pog)	$105\text{mm} \pm 8.0\text{mm}$	97.7mm	106.6mm	106.4mm
IMPA (L1-MP)	$95^{\circ} \pm 7.0^{\circ}$	93.3°	85.7°	85.9°
Interincisal angle (U1-L1)	$130^{\circ} \pm 6.0^{\circ}$	124.5°	135.2°	137.0°
Upper incisor inclination (U1-APo)	$28^{\circ} \pm 4.0^{\circ}$	28.6°	28.8°	23.0°
L1-APo	$22^{\circ} \pm 4.0^{\circ}$	27.0°	16.0°	20.0°
Overjet	$2.5\text{mm} \pm 2.5\text{mm}$	-2.0mm	3.9mm	2.3mm
Overbite	$2.5\text{mm} \pm 2.0\text{mm}$	2.0mm	1.7mm	0.8mm
Y-axis (SGn-SN)	$67^{\circ} \pm 5.5^{\circ}$	69.0°	68.2°	68.7°
Facial axis angle (Ba-Na/Pt-Gn)	$0^{\circ} \pm 4.0^{\circ}$	-1.1°	1.7°	-0.1°
SN	$75\text{mm} \pm 3.0\text{mm}$	66.6mm	67.4mm	67.5mm
FH-SN	$6^{\circ} \pm 4.0^{\circ}$	11.8°	10.9°	12.9°
SN-Ba	$131^{\circ} \pm 4.5^{\circ}$	131.0°	131.5°	131.2°
Wits appraisal	$-1\text{mm} \pm 1.0\text{mm}$	-5.4mm	-1.2mm	-3.7mm
Mandibular body length (Go-Me)	$75.4\text{mm} \pm 5.0\text{mm}$	62.9mm	64.7mm	70.2mm
Mandibular length (Co-Gn)	$112.3\text{mm} \pm 4.0\text{mm}$	100.5mm	107.9mm	108.3mm
Midfacial length (Co-A)	$88.2\text{mm} \pm 4.0\text{mm}$	71.5mm	82.8mm	79.8mm
Maxillary/mandibular differential (Co-Gn-Co-A)	$20\text{mm} \pm 4.0\text{mm}$	29.1mm	25.1mm	28.6mm
Nasolabial angle (Col-Sn-UL)	$102^{\circ} \pm 8.0^{\circ}$	113.7°	113.4°	115.5°
Upper lip to S-line	$0\text{mm} \pm 2.0\text{mm}$	-0.4mm	-1.7mm	-2.3mm
Lower lip to S-line	$0\text{mm} \pm 2.0\text{mm}$	1.3mm	-1.2mm	-2.3mm
Upper lip thickness	$1\text{mm} \pm 1.0\text{mm}$	2.4mm	2.8mm	3.9mm
Holdaway ratio (L1-NB/Pg-NB)	$2\% \pm 1.0\%$	-4.5%	1.7%	2.9%
H-angle (Pg'UL-Pg'Na')	$10^{\circ} \pm 4.0^{\circ}$	9.0°	8.5°	7.7°

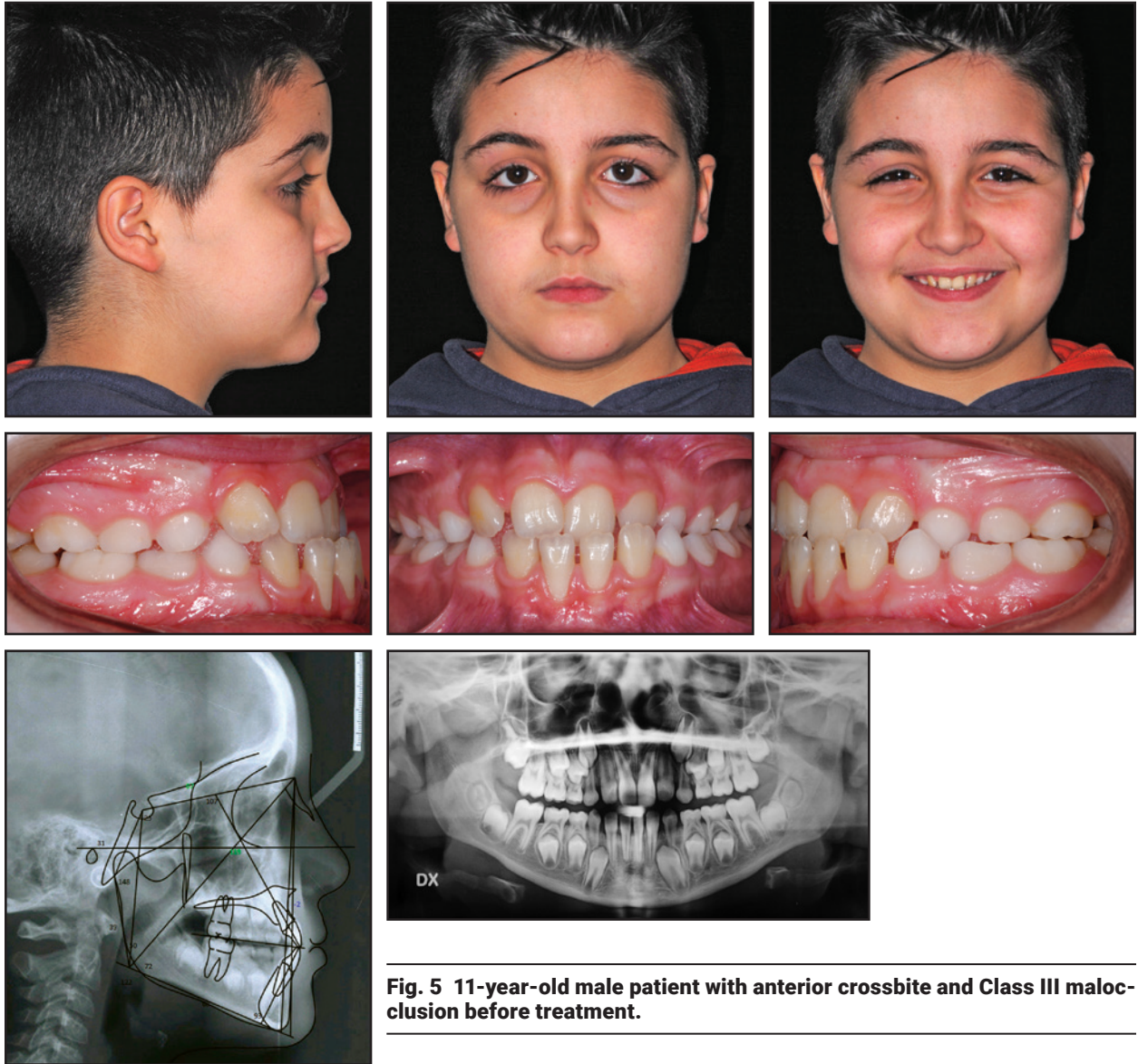


Fig. 5 11-year-old male patient with anterior crossbite and Class III malocclusion before treatment.

surgical insertion procedure. Another alternative would have been a functional appliance such as a Fränkel III, but this type of device may be less effective in correcting a retrognathic maxilla, since it induces downward and backward rotation of the mandible and its treatment effects are mainly dentoalveolar.²⁸ A Hybrid Hyrax appliance with a .2mm split-screw thread pitch was chosen to

maximize the skeletal effect of the protraction facemask while avoiding dental side effects.

Following the Easy Driver protocol, two mini-implants with interchangeable abutments (2mm × 9mm, Benefit system†) were inserted

†PSM Medical Solutions, Tuttlingen, Germany; www.psm-na.us. Distributed in the U.S. by Mondeal North America, Inc., Indio, CA; www.mondeal-ortho.com.

(Fig. 6). The Hybrid Hyrax was securely attached to the mini-implants with the fixation screws (Fig. 7A). The device was then positioned on the molars by applying seating pressure on the bands, which had been lined with cement (Fig. 7B). The mini-implant caps were tightened to complete placement.

After two weeks of acclimatization, expansion was begun with three daily activations, for a total of about .6mm of expansion per day. A week later, according to the Alt-RAMEC protocol, the split screw was activated in reverse for contraction. Expansion and contraction were alternated for seven weeks, ending in expansion. The protraction forces were then initiated, following Liou's procedure.²³

In conventional orthopedic Class III correction, the protraction forces are applied to rigid

sectional wires welded to the buccal side of the molar bands, with hooks in the canine regions. The required wire diameters are .059" on the palatal side (as with a palatal expansion screw) or .039" on the buccal side. This creates extremely stiff mechanical properties and an expansion capacity

*Forestadent GmbH, Pforzheim, Germany; www.forestadent.com.

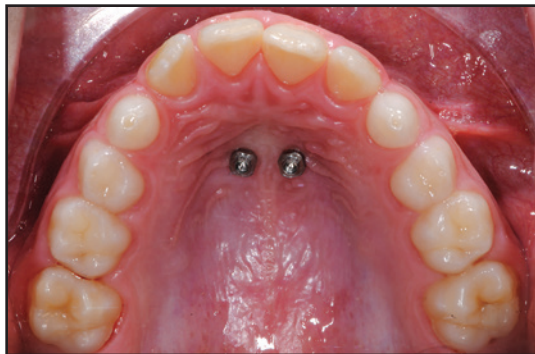


Fig. 6 Palatal mini-implants after insertion.

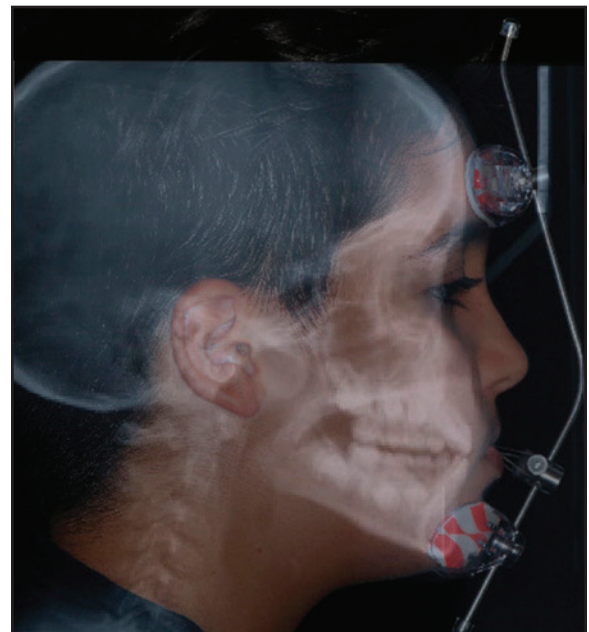


Fig. 8 Superimposition of lateral cephalogram and photograph of patient wearing facemask.



Fig. 7 A. Hybrid Hyrax* on top of mini-implant analogs. **B.** Appliance in place.

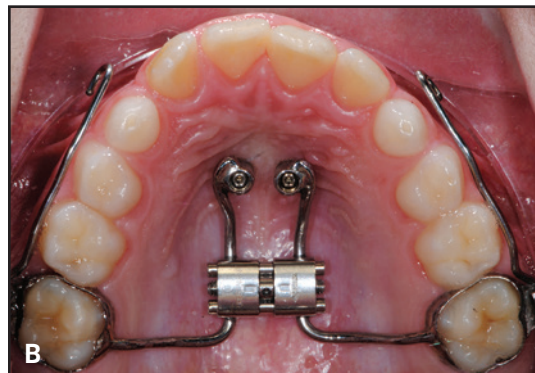

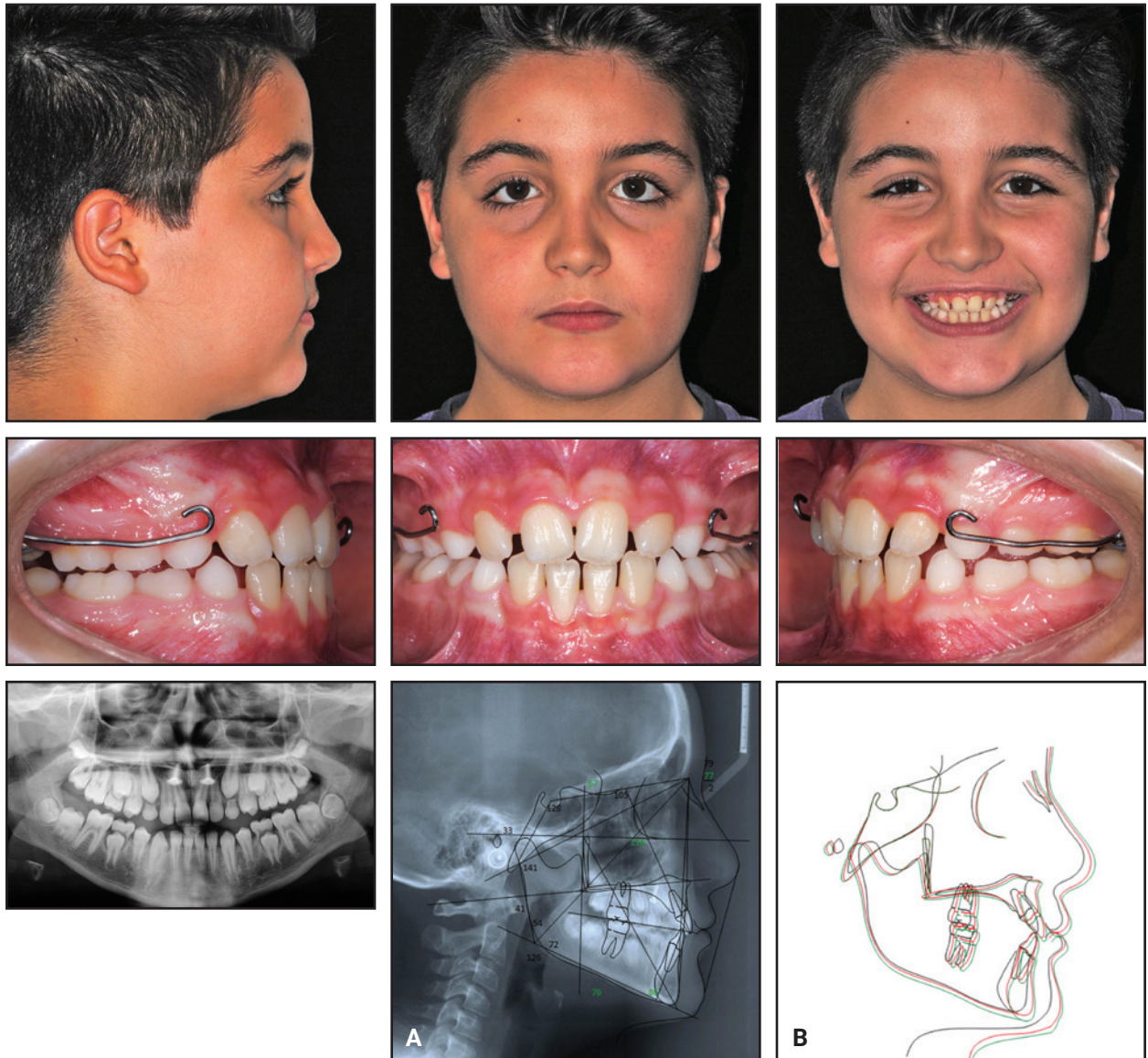


Fig. 9 A. Patient after 10 weeks of maxillary protraction. **B.** Superimposition of cephalometric tracings before (black) and after (red) treatment and 12 months after treatment (green).

of 10mm. In our case, elastics ($5/16"$, 16oz) were attached from the hooks of the Hybrid Hyrax appliance to the support bar of the protraction face-mask in a downward and forward direction, at 30° to the occlusal plane, to avoid anterior rotation of the maxilla.²⁹ The initial lateral cephalogram was superimposed on a photograph of the patient wearing a facial mask to confirm this angulation (Fig. 8). The elastics applied a force of 400g per side, as measured with a dynamometer.[‡] Results of the case confirmed the efficacy of our approach.

The recommended time for wearing the face-mask varies from 14 hours per day³⁰ to full-time,³¹ depending on the early Class III treatment protocol. Our patient was instructed to wear the face-mask 16 hours per day. His early Class III treatment was finished in 10 weeks (Fig. 9).

Discussion

This patient's overjet increased from -2mm to 3.9mm, a net anterior displacement of 5.9mm (Table 1). SNA increased by 4° , within the range of reported skeletal changes produced by facemask therapy.^{32,33} Overcorrection is not advised when treating skeletal Class III malocclusion because the aim is to maintain a deep overbite, which in turn controls maxillary growth through anterior contact and neurosensory signal stimulation.³⁴ In this case, the combination of facemask therapy and expansion had the added benefit of resolving asymmetry by correcting the mandibular slide to the left, as well as improving the gingival attach-

ment on the lower right central incisor by reducing occlusal trauma on the tooth.

The Easy Driver system facilitates safe and precise insertion of mini-implants in the anterior hard palate, making the Hybrid Hyrax method more accessible for less experienced clinicians. Additionally, the protocol allows the insertion of mini-implants and installation of the appliance in just one appointment.

REFERENCES

1. Williams, M.D.; Sarver, D.M.; Sadowsky, P.L.; and Bradley, E.: Combined rapid maxillary expansion and protraction facemask in the treatment of Class III malocclusions in growing children: A prospective long-term study, *Semin. Orthod.* 3:265-274, 1997.
2. Kokich, V.G.; Shapiro, P.A.; Oswald, R.; Koskinen-Moffett, L.; and Clarren, S.K.: Ankylosed teeth as abutments for maxillary protraction: A case report, *Am. J. Orthod.* 88:303-307, 1985.
3. Henry, P.J.: Clinical experiences with dental implants, *Adv. Dent. Res.* 13:147-152, 1999.
4. Kaya, D.; Kocadereli, I.; Kan, B.; and Tasar, F.: Effects of face-mask treatment anchored with miniplates after alternate rapid maxillary expansions and constrictions: A pilot study, *Angle Orthod.* 81:639-646, 2011.
5. De Clerck, H.; Cevidanes, L.; and Baccetti, T.: Dentofacial effects of bone-anchored maxillary protraction: A controlled study of consecutively treated Class III patients, *Am. J. Orthod.* 138:577-581, 2010.
6. Sar, C.; Arman-Ozgirpici, A.; Uckan, S.; and Yazici, A.C.: Comparative evaluation of maxillary protraction with or without skeletal anchorage, *Am. J. Orthod.* 139:636-649, 2011.
7. Nienkemper, M.; Wilmes, B.; Franchi, L.; and Drescher, D.: Effectiveness of maxillary protraction using a Hybrid Hyrax-facemask combination: A controlled clinical study, *Angle Orthod.* 85:764-770, 2015.
8. Wilmes, B.; Nienkemper, M.; Ludwig, B.; Kau, C.H.; and Drescher, D.: Early Class III treatment with a Hybrid Hyrax-Mentoplate combination, *J. Clin. Orthod.* 45:1-7, 2011.
9. Wilmes, B. and Drescher, D.: A miniscrew system with interchangeable abutments, *J. Clin. Orthod.* 42:574-580, 2008.
10. Wilmes, B.; Drescher, D.; and Nienkemper, M.: A miniplate system for improved stability of skeletal anchorage, *J. Clin. Orthod.* 43:494-501, 2009.

[‡]Correx Force Gauge, Haag-Streit Diagnostics, Köniz, Switzerland; www.haag-streit.com.

11. Wilmes, B.; Nienkemper, M.; and Drescher, D.: Application and effectiveness of a mini-implant- and tooth-borne rapid palatal expansion device: The Hybrid Hyrax, *World J. Orthod.* 11:323-330, 2010.
12. Wilmes, B.; Bowman, J.S.; and Baumgaertel, S.: Fields of application of mini-implants, in *Mini-Implants in Orthodontics: Innovative Anchorage Concepts*, ed. B. Ludwig, S. Baumgaertel, and J.S. Bowman, Quintessence Publishing Co., Inc., Hanover Park, IL, 2008, pp. 91-122.
13. Ludwig, B.; Glasl, B.; Bowman, J.S.; Drescher, D.; and Wilmes, B.: Miniscrew-supported Class III treatment with the Hybrid RPE Advancer, *J. Clin. Orthod.* 44:533-539, 2010.
14. Ngan, P.; Wilmes, B.; Drescher, D.; Martin, C.; Weaver, B.; and Gunel, E.: Comparison of two maxillary protraction protocols: Tooth-borne versus bone-anchored protraction facemask treatment, *Prog. Orthod.* 16:26, 2015.
15. Ludwig, B.; Baumgaertel, S.; Zorkun, B.; Bonitz, L.; Glasl, B.; Wilmes, B.; and Lissou, J.: Application of a new viscoelastic finite element method model and analysis of miniscrew-supported Hybrid Hyrax treatment, *Am. J. Orthod.* 143:426-435, 2013.
16. Nienkemper, M.; Wilmes, B.; Pauls, A.; and Drescher, D.: Maxillary protraction using a Hybrid Hyrax-facemask combination, *Prog. Orthod.* 14:1-8, 2013.
17. Lee, K.J.; Park, Y.C.; Park, J.Y.; and Hwang, W.S.: Miniscrew-assisted nonsurgical palatal expansion before orthognathic surgery for a patient with severe mandibular prognathism, *Am. J. Orthod.* 137:830-839, 2010.
18. Moon, W.; Wu, K.W.; MacGinnis, M.; Sung, J.; Chu, H.; Youssef, G.; and Machado, A.: The efficacy of maxillary protraction protocols with the micro-implant-assisted rapid palatal expander (MARPE) and the novel N2 mini-implant: A finite element study, *Prog. Orthod.* 16:16, 2015.
19. MacGinnis, M.; Chu, H.; Youssef, G.; Wu, K.W.; Machado, A.W.; and Moon, W.: The effects of micro-implant assisted rapid palatal expansion (MARPE) on the nasomaxillary complex: A finite element method (FEM) analysis, *Prog. Orthod.* 15:52, 2014.
20. Baccetti, T.; McGill, J.S.; Franchi, L.; McNamara, J.A. Jr.; and Tollaro, I.: Skeletal effects of early treatment of Class III malocclusion with maxillary expansion and face-mask therapy, *Am. J. Orthod.* 113:333-343, 1998.
21. Jager, A.; Braumann, B.; Kim, C.; and Wahner, S.: Skeletal and dental effects of maxillary protraction in patients with Angle class III malocclusion: A meta-analysis, *J. Orofac. Orthop.* 62:275-284, 2001.
22. Foersch, M.; Jacobs, C.; Wriedt, S.; Hechtner, M.; and Wehrbein, H.: Effectiveness of maxillary protraction using facemask with or without maxillary expansion: A systematic review and meta-analysis, *Clin. Oral Investig.* 19:1181-1192, 2015.
23. Liou, E.J.: Effective maxillary orthopedic protraction for growing Class III patients: A clinical application simulates distraction osteogenesis, *Prog. Orthod.* 6:154-171, 2005.
24. Franchi, L.; Baccetti, T.; Masucci, C.; and Defraia, E.: Early Alt-RAMEC and facial mask protocol in Class III malocclusion, *J. Clin. Orthod.* 45:601-609, 2011.
25. Masucci, C.; Franchi, L.; Giuntini, V.; and Defraia, E.: Short-term effects of a modified Alt-RAMEC protocol for early treatment of Class III malocclusion: A controlled study, *Orthod. Craniofac. Res.* 17:259-269, 2014.
26. Wilmes, B.; Ngan, P.; Liou, E.J.; Franchi, L.; and Drescher, D.: Early Class III facemask treatment with the Hybrid Hyrax and Alt-RAMEC protocol, *J. Clin. Orthod.* 48:84-93, 2014.
27. De Clerck, H.; Cevidanes, L.; and Baccetti, T.: Dentofacial effects of bone-anchored maxillary protraction: A controlled study of consecutively treated Class III patients, *Am. J. Orthod.* 138:577-581, 2010.
28. Baik, H.S.; Jee, S.H.; Lee, K.J.; and Oh, T.K.: Treatment effects of Fränkel functional regulator III in children with Class III malocclusions, *Am. J. Orthod.* 125:294-301, 2004.
29. Ngan, P.W.; Hagg, U.; Yiu, C.; and Wei, S.H.Y.: Treatment response and long-term dentofacial adaptations to maxillary expansion and protraction, *Semin. Orthod.* 3:255-264, 1997.
30. Westwood, P.V.; McNamara, J.A. Jr.; Baccetti, T.; Franchi, L.; and Sarver, D.M.: Long-term effects of Class III treatment with rapid maxillary expansion and facemask therapy followed by fixed appliances, *Am. J. Orthod.* 123:306-320, 2003.
31. Baccetti, T.; McGill, J.S.; Franchi, L.; McNamara, J.A. Jr.; and Tollaro, I.: Skeletal effects of early treatment of Class III malocclusion with maxillary expansion and face-mask therapy, *Am. J. Orthod.* 113:333-343, 1998.
32. Masucci, C.; Franchi, L.; Giuntini, V.; and Defraia, E.: Short term effects of a modified Alt RAMEC protocol for early treatment of Class III malocclusion: A controlled study, *Orthod. Craniofac. Res.* 17:259-269, 2014.
33. Nienkemper, M.; Wilmes, B.; Franchi, L.; and Drescher, D.: Effectiveness of maxillary protraction using a Hybrid Hyrax-facemask combination: A controlled clinical study, *Angle Orthod.* 85:764-770, 2014.
34. Ferro, A.; Nucci, L.P.; Ferro, F.; and Gallo, C.: Long-term stability of skeletal Class III patients treated with splints, Class III elastics, and chin cup, *Am. J. Orthod.* 123:423-434, 2003.