

# Submucous Cleft Palate and Velopharyngeal Insufficiency: Comparison of Speech Outcomes Using Three Operative Techniques by One Surgeon

Stephen R. Sullivan, M.D., M.P.H., Sivabalan Vasudavan, B.D.Sc., M.D.Sc., M.P.H., Eileen M. Marrinan, M.S., M.P.H., John B. Mulliken, M.D.

**Objective:** Our purpose was to compare speech outcomes among three primary procedures for symptomatic submucous cleft palate (SMCP): two-flap palatoplasty with muscular retropositioning, double-opposing Z-palatoplasty, or pharyngeal flap.

**Design:** Retrospective review.

**Setting:** Tertiary hospital.

**Patients, Participants:** All children with SMCP treated by the senior author between 1984 and 2008.

**Interventions:** One of three primary procedures: two-flap palatoplasty with muscular retropositioning, double-opposing Z-palatoplasty, or pharyngeal flap.

**Main Outcome Measures:** Speech outcome and need for a secondary operation were analyzed among procedures. Success was defined as normal or borderline competent velopharyngeal function. Failure was defined as persistent borderline insufficiency or velopharyngeal insufficiency with recommendation for a secondary operation.

**Results:** We identified 58 patients with SMCP who were treated for velopharyngeal insufficiency. We found significant differences in median age at operation among the procedures ( $p < .001$ ). Two-flap palatoplasty with muscular retropositioning ( $n = 24$ ), double-opposing Z-palatoplasty ( $n = 19$ ), and pharyngeal flap ( $n = 15$ ) were performed at a median of 2.5, 3.6, and 9.5 years, respectively. There were significant differences in success among procedures ( $p = .018$ ). Normal or borderline competent function was achieved in 6/20 (30%) patients who underwent two-flap palatoplasty, 10/15 (67%) following double-opposing Z-palatoplasty, and 11/12 (92%) following pharyngeal flap. Among patients treated with palatoplasty, success was independent of age at operation ( $p = .16$ ).

**Conclusions:** Double-opposing Z-palatoplasty is more effective than two-flap palatoplasty with muscular retropositioning. For children older than 4 years, primary pharyngeal flap is also highly successful but equally so as a secondary operation and can be reserved, if necessary, following double-opposing Z-palatoplasty.

KEY WORDS: *cleft palate, double-opposing Z-palatoplasty, Furlow palatoplasty, palatoplasty, pharyngeal flap, submucous, velopharyngeal insufficiency*

---

Dr. Sullivan was Fellow, Pediatric and Craniomaxillofacial Surgery, Harvard Medical School, Department of Plastic and Oral Surgery, Children's Hospital, Boston, Massachusetts, and currently is Assistant Professor of Surgery and Pediatrics, Warren Alpert Medical School of Brown University and Rhode Island and Hasbro Children's Hospital, Providence, Rhode Island. Dr. Vasudavan was Fellow, Craniofacial and Cleft Lip/Palate Orthodontics, and currently is Adjunct Faculty Staff Member, Department of Dentistry, Children's Hospital Boston, and Visiting Lecturer, Department of Developmental Biology, Harvard School of Dental Medicine, Boston, Massachusetts. Ms. Marrinan is Director, Central New York Cleft and Craniofacial Center, State University of New York, Upstate Medical University Hospital, Syracuse, New York. Dr. Mulliken is Professor of Surgery, Harvard Medical School, Department of Plastic and Oral Surgery, Children's Hospital, Boston, Massachusetts.

Submitted July 2009; Accepted August 2010.

Submucous cleft palate (SMCP) occurs in 0.02% to 0.08% of children and presents in a spectrum of velopharyngeal abnormalities (Crikelair et al., 1970; Weatherley-White et al., 1972; Kaplan, 1975; Shprintzen et al., 1985; Garcia Velasco et al., 1988). Overt SMCP is characterized by bifid uvula, deficient midline muscle with zona pellucida, and an osseous notch of the hard palate (Roux, 1825; Kelly, 1910; Calnan, 1954; Sommerlad et al., 2004). Occult SMCP appears anatomically normal (Crikelair et

---

Address correspondence to: Dr. John B. Mulliken, Department of Plastic and Oral Surgery, Children's Hospital, 300 Longwood Avenue, Hunnewell 1, Boston, MA 02115. E-mail john.mulliken@childrens.harvard.edu.

DOI: 10.1597/09-127

al., 1970; Kaplan, 1975; Gosain et al., 1996). The palatal defect can be identified by dissection (Kaplan, 1975) or by nasopharyngoscopy, which reveals a flat or concave nasal surface during speech, rather than the expected convexity (Lewin et al., 1980). The diagnosis of an occult SMCP is often delayed until speech abnormalities associated with velopharyngeal insufficiency become apparent (Porterfield and Traube 1965; Garcia Velasco et al., 1988; Park et al., 2000; David et al., 2006; Isotalo et al., 2008). Thus, primary surgical repair is late.

Velopharyngeal insufficiency is characterized by hypernasal resonance and decreased intraoral pressure causing weak pressure consonants and sometimes audible nasal emission during speech (Lewin, 1984; Shprintzen and Golding-Kushner, 1989; Smith and Guyette, 2004). Velopharyngeal insufficiency occurs in only 5% to 10% of patients with SMCP (Abdel-Aziz, 2007; Gosain et al., 1996; Lewin et al., 1980; Shprintzen et al., 1985; Weatherley-White et al., 1972; Ysunza et al., 2001). Treatment of velopharyngeal insufficiency begins with the speech pathologist. A phonological profile documents deviant compensatory articulation patterns associated with velopharyngeal insufficiency (e.g., glottal stops, pharyngeal fricatives, and laryngeal fricatives). A therapeutic plan is outlined to eliminate these patterns and to establish normal oral placement for consonant production (albeit with decreased intraoral pressure). Multiview videofluoroscopy or nasoendoscopy are undertaken to assess the palate, velopharyngeal gap, and movement of pharynx. Studies are reviewed with the surgeon, and an operative plan is determined.

The next step is to determine the most appropriate operation; this is controversial. Reported techniques include palatoplasty (e.g., two-flap, VY pushback, Veau-Wardill-Kilner, von Langenbeck) with or without muscular repositioning (Calnan, 1954; Porterfield and Traube, 1965; Crikelair et al., 1970; Pensler and Bauer, 1988; Bardach et al., 1992; Park et al., 2000; Inman et al., 2005; David et al., 2006), double-opposing Z-palatoplasty (Furlow, 1986; Garcia Velasco et al., 1988; Chen et al., 1996; Lindsey and Davis, 1996; Kirschner et al., 1999; Seagle et al., 1999; Park et al., 2000; LaRossa et al., 2004; Perkins et al., 2005), pharyngeal flap (Crikelair et al., 1970; Weatherley-White et al., 1972; Abyholm, 1976; Porterfield et al., 1976; Seyfer et al., 1988; Seagle et al., 1999; Park et al., 2000; Husein et al., 2004; Abdel-Aziz, 2007), minimal incision palatopharyngoplasty (Mendoza et al., 1994; Ysunza et al., 2001), and customized combinations of palatal and pharyngeal operations (Calnan, 1954; Hoopes et al., 1970; Kaplan, 1975; Minami et al., 1975; Abyholm, 1976; Porterfield et al., 1976; Park et al., 2000; Ysunza et al., 2001). Successful correction of velopharyngeal insufficiency varies widely in these reports; secondary operative rates range from 0 to 97%.

Meaningful comparisons among studies are limited by different operative techniques, diverse patient populations

with varying anatomic and physiologic profiles, procedure timing, and subjective and inconsistent outcome measures. Studies comparing techniques do exist but are further compromised by the involvement of multiple surgeons and variance in experience (Minami et al., 1975; Witt, Wahlen, et al., 1998; Kirschner et al., 1999; Park et al., 2000; Ysunza et al., 2001; LaRossa et al., 2004; Inman et al., 2005; Lam et al., 2007). The purpose of this study was to describe the evolution of one surgeon's methods and to compare speech results and need for a secondary operation among three primary operative techniques (i.e., two-flap palatoplasty with muscular repositioning, double-opposing Z-palatoplasty, or pharyngeal flap).

## MATERIALS AND METHODS

After approval by the Committee on Clinical Investigation, we identified and reviewed the charts of all patients who had an operation for SMCP. An operation was indicated in all patients because of evidence of velopharyngeal insufficiency. Patients underwent preoperative physical examination, speech evaluation, and, if cooperative, multi-view videofluoroscopy. Patients with velocardiofacial syndrome (22q11) were excluded from the study due to additional anatomic differences seen in these patients (e.g., platybasia, hypoplastic adenoid pad, and pharyngeal hypotonia) when compared with other children with SMCP (Arvystas and Shprintzen, 1984; Williams et al., 1987; Goldberg et al., 1993; Ford et al., 2000). The senior author performed all operations between 1984 and 2008. Data collected included date of birth, sex, hearing loss, syndrome/association diagnosis, type of SMCP (overt diagnosed by clinical examination or occult diagnosed by viewing the nasal surface of the soft palate via nasopharyngoscopy during speech production), presence of cleft lip, age at primary operation, type of primary operation (two-flap palatoplasty, double-opposing Z-palatoplasty, or pharyngeal flap), videofluoroscopic results, preoperative and postoperative speech assessment, postoperative complications, need for a secondary operation, and duration of follow-up.

### Operative Techniques

#### *Two-Flap Palatoplasty With Muscular Repositioning*

The senior author's initial approach to patients younger than 4 to 5 years with SMCP was a two-flap palatoplasty with muscular repositioning, as previously described (Sullivan et al., 2009). The anteriorly displaced tensor and levator veli palatini muscles were incised from their abnormal attachment to the posterior palatine edge, dissected from the oral and nasal mucosa, repositioned, and apposed. In retrospect, the repositioning would be described as type IIb (Andrades et al., 2008). The hamulus was fractured to free the tensor veli palatini tendon and to facilitate posteromedial displacement of the velar muscles

and mucoperiosteal flaps for a three-layer soft palatal repair. A gauze palatal pack, soaked in Balsam of Peru, was sutured to the alveolar ridges to support the mucoperiosteal flaps and minimize bleeding, pain, and dead space under the flaps.

### ***Double-Opposing Z-Palatoplasty***

Concerned by a perceived high rate of velopharyngeal insufficiency following two-flap palatoplasty with muscular repositioning, the senior author began performing the double-opposing Z-palatoplasty in 1997. The operative technique was as described by Furlow (1986).

### ***Pharyngeal Flap***

A primary pharyngeal flap was considered for patients who were 4 to 5 years of age or older and able to participate in videofluoroscopy (Garcia Velasco et al., 1988; Marrinan et al., 1998; Sloan, 2000; Salyer et al., 2006). The lateral pharyngeal wall motion (percentage of closure by medial movement), palatal length (short, normal, long), velopharyngeal gap size (small, moderate, gross), and defect pattern (coronal, sagittal, circular) were recorded. Pharyngeal flap width (narrow, medium, wide, very wide, subobstructing) was tailored based on lateral pharyngeal wall motion and was relative to the size of the pharynx. The differences between a medium, wide, and very wide flap requires judgment and experience. For example, if the lateral pharyngeal wall motion was 50%, a wide pharyngeal flap was designed such that it was 50% of the width of the pharynx; an additional 10% width was added to each side to account for contraction of the flap and pharynx. If the tonsils were enlarged (2+ or greater), tonsillectomy was done at least 8 weeks prior to the pharyngeal flap. Eight children had a preoperative tonsillectomy, and 6 also had an adenoidectomy.

The velum was split at the midline halfway to the junction with the hard palate. Trapezoidal-shaped nasal mucosal flaps were incised and separated from the oral mucosa. The superiorly-based flap was elevated off the buccopharyngeal fascia to above the level of the soft palate. The distal end of the pharyngeal flap was placed onto the nasal surface of the mid soft palate and fixed with three mattress sutures. The pharyngeal donor site was closed by advancement of the lateral mucosal walls, sutured to the fascia superiorly and apposed inferiorly. Number 12 or 14 French red rubber catheters, placed through the nose and lateral portals, helped in the closure. Lateral port control (Hogan, 1973) was not done. The nasal mucosal flaps were sutured to the base of the flap to line the raw surface, and the velum was repaired.

### **Speech Assessment**

Patients were followed annually in our interdisciplinary clinic. Speech pathologists, who specialize in cleft palate

(CP), completed a perceptual assessment using the Pittsburgh Weighted Values for Speech Symptoms Associated With Velopharyngeal Incompetence instrument (McWilliams and Philips, 1979). Speech outcomes were objectively based on three structurally correctable variables: resonance (normal, mildly hyponasal, mixed hypo-hypernasal, inconsistent mildly hypernasal, mildly hypernasal, moderately hypernasal, severely hypernasal), intraoral pressure (normal, decreased), and nasal emission (absent by mirror examination, visible, audible, turbulent). Children who were too young to complete the entire evaluation were assessed for resonance and intraoral pressure. Because children will often describe the mockery of others at their funny voice, all children and families were asked if speech posed a personal or social problem when talking to others (Albery et al., 1982). Overall velopharyngeal competence was graded as (1) normal (normal or mildly hyponasal resonance, absence or inconsistent visible nasal emission by mirror examination, normal intraoral pressure, no personal/social problems), (2) borderline competent (inconsistent mildly hypernasal, visible or inconsistent audible nasal emission, normal intraoral pressure, no personal/social problems), (3) borderline insufficient (mildly hypernasal resonance, audible or turbulent nasal emission or inconsistent decreased intraoral pressure, or a personal/social problem), and (4) insufficient (moderate or severe hypernasal resonance, audible or turbulent nasal emission, decreased intraoral pressure, personal/social problems). Normal or borderline competency was categorized as a success, while borderline insufficiency or insufficiency was categorized as a failure. Articulation errors and voice quality were assessed but not included in the grade of speech outcome as they are addressed by preoperative speech therapy and are not corrected by an operation. We also recorded the number of patients for whom a secondary operation was recommended because of failure.

The need for a revisionary operation to correct airway obstruction following pharyngeal flap was also recorded (e.g., postoperative tonsillectomy, adenoidectomy, flap division, or dilation of pharyngeal ports). Polysomnography was conducted if a child evidenced symptoms of obstructive sleep apnea.

### **Statistical Analyses**

Patient characteristics were summarized and compared among operative techniques. Medians of continuous variables were analyzed using the Kruskal-Wallis test. Bonferroni's method was used to correct for multiple comparisons. Proportions were analyzed using Fisher's exact test. To evaluate for a possible association between the age at primary palatoplasty and need for a secondary operation, we performed a logistic regression and present the odds ratio (OR) and 95% confidence interval (95% CI). Continuous data were expressed as median  $\pm$  standard deviation. All calculated *p* values were two-tailed and

**TABLE 1 Patient Characteristics, Overall and by Primary Operation**

Patient Characteristic	All Patients (N = 58) (%)	Two-Flap Palatoplasty (n = 24) (%)	Double-Opposing Z-Palatoplasty (n = 19) (%)	Pharyngeal Flap (n = 15) (%)	p Value*
Age at primary operation (years)					
Median ± SD	3.8 ± 3.5	2.5 ± 1.9	3.6 ± 2.9	9.5 ± 2.7	<.001
Range	0.7–12.3	0.7–7.5	1.3–12.3	4.3–12.3	
Duration of postoperative follow-up (years)					
Median ± SD	2.0 ± 3.5	3.7 ± 4.3	1.1 ± 2.6	0.7 ± 2.0	.001
Male:female ratio	34:24 (59:41)	14:10 (58:42)	11:8 (58:42)	9:6 (60:40)	1.0
Overt:occult SMCP	43:15	23:1	16:3	4:11	<.001
Hearing loss	10 (17)	4 (17)	2 (11)	4 (27)	.6
Syndrome/association	16 (28)	5 (21)	5 (26)	6 (40)	.5
Cleft lip	8 (14)	5 (21)	3 (16)	0 (0)	.12
Completed postoperative speech evaluation to date	47 (94)	20 (83)	15 (79)	12 (80)	1.0
Oronasal fistula	1 (2)	0 (0)	1 (5)	0 (0)	.6

\* p values were calculated using the Kruskal-Wallis test to compare median age and length of follow-up and Fisher's exact test to compare all other proportions.

considered significant if  $<.05$ . Statistical analyses were performed using Stata version 8 (Statacorp, College Station, TX).

## RESULTS

### Patient Population

We reviewed 58 patients with SMCP and velopharyngeal insufficiency (Table 1). As expected, there were significant differences in age at operation among the three techniques ( $\chi^2[2, 58] = 27.0, p < .001$ ). Patients who had a double-opposing Z-palatoplasty were older than those who had a two-flap palatoplasty ( $\chi^2[1, 43] = 6.2, p = .04$ , Bonferroni corrected). Patients managed with a pharyngeal flap were significantly older at the time of operation as compared with those treated with either two-flap palatoplasty or double-opposing Z-palatoplasty ( $\chi^2[1, 39] = 22.7, p < .001$ , and  $\chi^2[1, 34] = 12.4, p = .001$ , respectively; Bonferroni corrected) and were also more likely to have an occult SMCP ( $\chi^2[2, 58] = 24.5, p < .001$ ). The age at diagnosis and treatment was also significantly delayed for children with occult SMCP (median, 7; range, 3 to 12 years) when compared with those with overt SMCP (median, 3.4; range, 0.7 to 12 years;  $\chi^2[1, 57] = 12.4, p < .001$ ). A syndrome or association was diagnosed in 16 of 58 patients, with 5 treated with two-flap palatoplasty (Ectrodactyly-ectodermal dysplasia cleft, limb-mammary, Treacher Collins, Nagai, and an unknown syndrome), 5 treated with a double-opposing Z-palatoplasty (Stickler, VATER, FG, and 2 unknown), and 6 who underwent a pharyngeal flap (Asperger, Loey-Dietz, Kallman, Angelman, Neurofibromatosis, and CHARGE).

### Speech Outcomes: Operative Technique and Age at Operation

Postoperative perceptual speech results were available for 47 patients (Table 2). Overall velopharyngeal function, resonance, intraoral pressure, voice quality, and operative

failure, necessitating a secondary operation, were significantly different among treatment groups (Table 2).

### Palatoplasty (Two-Flap Palatoplasty With Muscular Retropositioning and Double-Opposing Z-Palatoplasty)

Postoperative speech results were available for 20 patients treated with two-flap palatoplasty with muscular retropositioning (Table 2). Operative success was achieved in 6 patients (30%). Thus, a secondary operation was recommended for 14 children (70%) due to persistent velopharyngeal insufficiency or borderline insufficiency. Most children had persistent visible or audible nasal emission, some degree of hypernasal resonance, and reduced intraoral pressure.

Postoperative speech results were available for 15 patients treated with a double-opposing Z-palatoplasty (Table 2). This procedure was successful in 10 children (67%), and a secondary pharyngeal flap was recommended for 5 children (33%). Most patients had visible nasal air emission but normal nasal resonance and normal intraoral pressure.

We compared characteristics between those patients who did and did not require a secondary operation following palatoplasty (Table 3) and found no difference in the median age at palatoplasty ( $\chi^2[1, 35] = 0.6, p = .4$ ). In addition, we found no relationship between age at palatoplasty and subsequent need for a secondary operation (OR = 0.82; 95% CI = 0.62 to 1.09,  $p = .16$ ) nor overt versus occult and need for a secondary operation ( $\chi^2[1, 35] = 0.8, p = .6$ ). Furthermore, primary palatoplasty was performed before 2 years of age on 12 patients; the procedure was a two-flap palatoplasty in 10 and a double-opposing Z-palatoplasty in two patients. Postoperative speech results were available for 8 children, and 3 (38%) required a secondary operation due to persistent velopharyngeal insufficiency. Notably, if the repair was done before 2 years of age, children were no less likely to need a secondary operation than those repaired after 2 years of age ( $p = .4$ ).

**TABLE 2 Postoperative Results of Perceptual Speech Evaluation and Need for a Secondary Operation, Overall and by Primary Operation**

	<i>All Patients</i> ( <i>n</i> = 47) (%)	<i>Two-Flap Palatoplasty</i> ( <i>n</i> = 20) (%)	<i>Double-Opposing</i> <i>Z-Palatoplasty</i> ( <i>n</i> = 15) (%)	<i>Pharyngeal Flap</i> ( <i>n</i> = 12) (%)	<i>p Value*</i>
Age at speech evaluation (years)					
Median $\pm$ SD	6.0 $\pm$ 3.4	5.2 $\pm$ 3.2	5.4 $\pm$ 3.2	10.7 $\pm$ 2.9	.007
Velopharyngeal function					.017
Normal	22 (47)	5 (25)	7 (47)	10 (83)	
Borderline competency	5 (11)	1 (5)	3 (20)	1 (8)	
Borderline insufficiency	9 (19)	7 (35)	2 (13)	1 (8)	
Insufficiency	11 (23)	7 (35)	3 (20)	0 (0)	
Resonance					.046
Normal	20 (43)	5 (26)	5 (33)	10 (83)	
Mildly hyponasal	2 (4)	0 (0)	2 (13)	0 (0)	
Mixed hypohypernasal	1 (2)	1 (5)	0 (0)	0 (0)	
Inconsistent mildly hypernasal	5 (11)	1 (5)	3 (20)	1 (8)	
Mildly hypernasal	5 (11)	3 (16)	1 (7)	1 (8)	
Moderately hypernasal	8 (17)	5 (26)	3 (20)	0 (0)	
Severely hypernasal	5 (11)	4 (21)	1 (7)	0 (0)	
Not recorded	1	1	0	0	
Intraoral pressure					.035
Normal	30 (65)	9 (45)	10 (67)	11 (92)	
Decreased	16 (35)	10 (55)	5 (33)	1 (8)	
Not recorded	1	1	0	0	
Nasal emission					.4
Absence by mirror examination	8 (18)	3 (15)	1 (8)	4 (33)	
Visible	28 (62)	11 (55)	10 (77)	7 (58)	
Audible or turbulent	9 (20)	6 (30)	2 (15)	1 (8)	
Not recorded	2	0	2	0	
Personal/social problems reported by child or parent					.001
No	22 (47)	6 (30)	10 (67)	11 (92)	
Yes	25 (53)	14 (70)	5 (33)	1 (8)	
Oronasal fistula	1 (2)	0 (0)	1 (7)	0 (0)	.6
Secondary operation recommended	20 (43)	14 (70)	5 (33)	1 (8)	.002

\* *p* values were calculated using the Kruskal-Wallis test to compare median age and Fisher's exact test to compare all other proportions.

### Pharyngeal Flap

The median preoperative lateral pharyngeal wall motion was 60% (range, 0%–90%). Most children had a short or normal-length palate with a small or medium circular velopharyngeal closure defect (Figs. 1 through 3). The pharyngeal flap width was tailored based on these findings (Fig. 4).

Postoperative speech results were available for 12 patients (Table 2). Velopharyngeal function was normal or borderline competent in 11 patients (92%); only one

patient had persistent borderline velopharyngeal insufficiency but improved relative to preoperative evaluation. None of the patients demonstrated hyponasal speech, obstructive sleep apnea, or flap dehiscence.

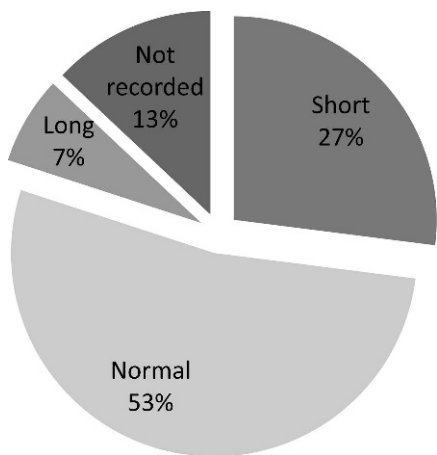
### DISCUSSION

SMCP is rare, and only 5% to 10% of these patients exhibit velopharyngeal insufficiency (Weatherley-White et al., 1972; Lewin et al., 1980; Shprintzen et al., 1985; Gosain et al., 1996; Ysunza et al., 2001; Abdel-Aziz, 2007). There

**TABLE 3 Characteristics of Patients Who Did or Did Not Require a Secondary Operation Following Palatoplasty (Two-Flap Palatoplasty With Muscular Retropositioning or Double-Opposing Z-Palatoplasty)**

<i>Patient Characteristic</i>	<i>Secondary Operation (n = 19) (%)</i>	<i>No Secondary Operation (n = 16) (%)</i>	<i>p Value*</i>
Age at primary operation (years)			
Median $\pm$ SD	3.4 $\pm$ 1.6	3.7 $\pm$ 3.4	.4
Range	0.7–12.3	1–7.5	
Male:female ratio	10:9 (53:47)	12:4 (75:25)	.3
Overt:occult SMCP	16:3	15:1	.6
Syndrome/association	5 (26)	4 (25)	1.0
Cleft lip	3 (16)	4 (25)	.7

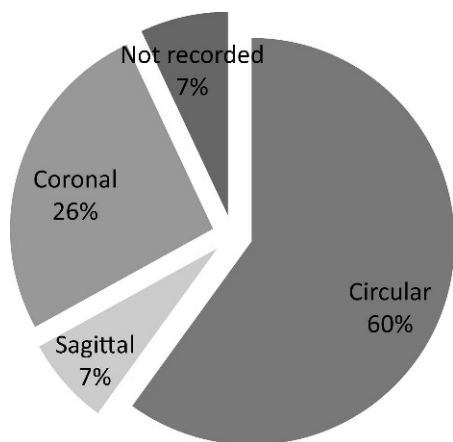
\* *p* values were calculated using the Kruskal-Wallis test to compare median age and Fisher's exact test to compare all other proportions.



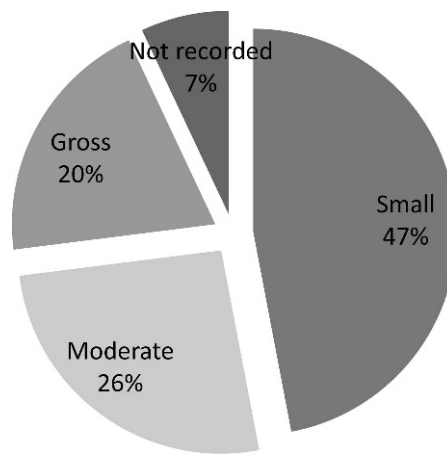
**FIGURE 1** Videofluoroscopic results. Percentage of patients by estimated palatal length.

are few clinical audits that compare techniques and document long-term results by a single surgeon (Seagle et al., 1999). The wide spectrum in anatomic and functional severity further complicates the diagnosis and treatment of SMCP (Crikelair et al., 1970; Kaplan, 1975; Garcia Velasco et al., 1988; Gosain et al., 1996). The most appropriate age at operation and technique are debated. We reviewed speech outcomes in patients with SMCP treated by one surgeon using one of three primary operative techniques (two-flap palatoplasty, double-opposing Z-palatoplasty, or pharyngeal flap). We found significant differences in success, speech characteristics, and necessity for a secondary procedure among the three procedures.

Speech results were disappointing in our series of children who had two-flap palatoplasty and muscular repositioning. Most children (70%) required a secondary pharyngeal flap. Results in the literature vary considerably. Some surgeons, even those who performed radical levator muscle repositioning, have also shown relatively poor results, with secondary operative rates ranging from 28% to



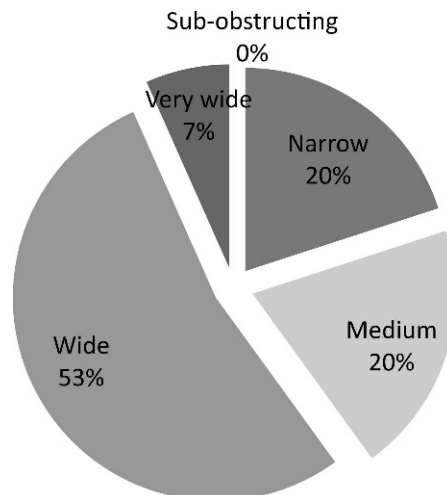
**FIGURE 2** Videofluoroscopic results. Percentage of patients by velopharyngeal closure pattern.



**FIGURE 3** Videofluoroscopic results. Percentage of patients by velopharyngeal defect size.

70% (Porterfield and Traube, 1965; Porterfield et al., 1976; Park et al., 2000; Sommerlad et al., 2004; David et al., 2006). Perhaps heterogenous anatomical abnormalities are a cause of variable results. Sommerlad and colleagues (2004) presented a thorough review of speech outcome as well as anatomic severity of SMCP. Anatomic severity of the SMCP did not correlate with the degree of speech abnormality preoperatively but was a predictor of surgical outcome postoperatively. While less severe SMCP was associated with increased need for a secondary operation, a careful review of the data demonstrated a greater degree of improvement for those with more severe SMCP as compared with those with occult SMCP. Although we did not grade the anatomic severity beyond overt versus occult SMCP, we found no relationship between severity and need for a secondary operation following palatoplasty.

The children in our series who had a two-flap palatoplasty with muscular repositioning underwent the operation at a younger age than those treated with a double-opposing Z-palatoplasty; however, few children had



**FIGURE 4** Percentage of patients by width of pharyngeal flap.

palatoplasty prior to 1 to 2 years of age. The poor speech results we and others observed may be due to repair at too advanced of an age, best described as a delayed primary palatoplasty.

Age at palatoplasty must be considered in relation to age of speech production and articulation (Trost, 1981; Dorf and Curtin, 1982). Spoken words typically begin at approximately 12 months of age. This has been shown to be a critical age as velopharyngeal competence is attained more often in infants with CP (Veau I–IV) when the palate is repaired before 1 year of age (Dorf and Curtin, 1982; Marrinan et al., 1998; Rohrich et al., 2000; Chapman et al., 2008; Sullivan et al., 2009). Early repair of SMCP has also been proposed (Calnan, 1954; Porterfield and Traube, 1965; Pensler and Bauer, 1988; Scheuerle and Habal, 2007), but the relatively late age of presentation usually delays correction (Porterfield and Traube, 1965; Crikelair et al., 1970; Park et al., 2000; David et al., 2006; Isotalo et al., 2008). In our series, the median age of treatment was 3.8 years. Other investigators have also reported an advanced average age of treatment at 3 to 5 years (Porterfield and Traube, 1965; Porterfield et al., 1976; Park et al., 2000; David et al., 2006; Isotalo et al., 2008).

Some who advocate for early repair presented small studies, which lacked power for meaningful analysis. Pensler and Bauer (1988) advocated early repair of SMCP based on a small series. They documented normal speech in six of eight children operated on before 2 years of age but in only one of seven if the operation was delayed until after 2 years of age. Likewise, Scheuerle and Habal (2007) recommended palatoplasty by 6 months of age based on an experience with 13 patients, but they provided no detailed patient information. Nevertheless, they attributed their 0% secondary operative rate to early repair.

We documented that those children who were surgically managed before 2 years of age were no more likely to attain postoperative velopharyngeal competency than those treated after 2 years of age. In addition, among all patients treated with palatoplasty (two-flap palatoplasty with muscular repositioning or double-opposing Z-palatoplasty), we found age at operation to be independent of the need for a secondary operation. Perhaps any operation, regardless of technique, after the critical age of 1 year would be less likely to achieve optimal speech outcome when compared with those repaired at an early age. Nevertheless, most authors recommend postponing operative repair for SMCP and waiting until speech is sufficient to allow thorough evaluation of velopharyngeal function (Kaplan, 1975; Minami et al., 1975; Porterfield et al., 1976; Garcia Velasco et al., 1988; Seagle et al., 1999; Sloan, 2000; Ysunza et al., 2001; Salyer et al., 2006). Furthermore, few children with SMCP will develop velopharyngeal insufficiency and require an operation (Weatherley-White et al., 1972; Kaplan, 1975; Shprintzen et al., 1985; Garcia Velasco et al., 1988; McWilliams, 1991; Gosain et al., 1996; Seagle et al., 1999; Ysunza et al., 2001; Abdel-Aziz, 2007; Isotalo et al., 2007). A

child with an overt SMCP puts the surgeon in a difficult position: operate early and perform an unnecessary operation, or wait until an age when velopharyngeal insufficiency is demonstrable and risk a poor speech outcome.

Regardless of the age at operation, we found double-opposing Z-palatoplasty to be more effective (67% success) than two-flap palatoplasty with muscular repositioning (30% success). Other investigators have also published favorable results using this technique, with reported secondary operative rates as low as 7.2% (Furlow 1986; Garcia Velasco et al., 1988; Brothers et al., 1995; Chen et al., 1996; Lindsey and Davis 1996; Gunther et al., 1998; Kirschner et al., 1999; Seagle et al., 1999; Park et al., 2000; LaRossa et al., 2004; Perkins et al., 2005). Palatal lengthening obtained by this operation probably explains its success as compared to two-flap palatoplasty with muscular repositioning. Most patients in our series had a small circular velopharyngeal gap with a short or normal palatal length; these are the very patients most likely to benefit from this operation (Furlow, 1986; Chen et al., 1994; Seagle et al., 1999; D'Antonio et al., 2000; Park et al., 2000; Sie and Gruss, 2002; Dailey et al., 2006). Therefore, we recommend double-opposing Z-palatoplasty as the primary operation for children with SMCP and documented velopharyngeal insufficiency. After age 4 to 5 years, children are usually cooperative enough to complete videofluoroscopic assessment and are considered candidates for either a double-opposing Z-palatoplasty or pharyngeal flap. In our small series of patients older than 4 years treated with double-opposing Z-palatoplasty, success was noted in all cases.

The tailored pharyngeal flap was the most effective operative technique for SMCP. Operative success was obtained in 92% patients. Several other investigators have also recommended a primary pharyngeal flap. Indeed, it has the highest reported success, with 80% to 90% of patients demonstrating normal speech (Porterfield and Traube, 1965; Weatherley-White et al., 1972; Abyholm, 1976; Porterfield et al., 1976; Shprintzen et al., 1979; Seyfer and Simon, 1989; Seagle et al., 1999; Park et al., 2000; Husein et al., 2004; Abdel-Aziz, 2007). Despite its proven efficacy, many surgeons avoid a primary pharyngeal flap, especially in young children, for fear of complications such as hyponasal speech and obstructive sleep apnea (Pensler and Bauer, 1988). We did not find evidence to support these fears in this sample of patients; neither hyponasality nor sleep apnea was documented. Nevertheless, we recognize that these complications do occur. We have documented hyponasality in 8.7% and sleep apnea in 2.5% of nonsyndromic patients with CP who required a pharyngeal flap (Sullivan et al., 2010). With careful consideration of lateral pharyngeal wall motion, surgeons experienced with constructing a tailored pharyngeal flap also report hyponasality in 3% to 27% of patients (Hogan, 1973; Shprintzen et al., 1979; Morris et al., 1995; Canady et al., 2003; Cable et al., 2004; Dailey et al., 2006; Lam et al., 2007) and low incidence of sleep apnea at 0% to 3.4% (Ysunza et al., 1993;

Hofer et al., 2002; Ysunza et al., 2002; Husein et al., 2004; Dailey et al., 2006; Salyer et al., 2006; Abdel-Aziz, 2007; Chegar et al., 2007; Isotalo et al., 2008). Enlarged tonsils must also be considered as hypertrophy, and posterior displacement into the oropharynx can obstruct the lateral ports and nasal airway (Ysunza et al., 1993; Chegar et al., 2007). Some authors have proposed routine tonsillectomy and adenoidectomy 3 to 4 months before a pharyngeal flap to minimize the risk of obstructive sleep apnea (Ysunza et al., 1993; Ysunza et al., 2001; Ysunza et al., 2002).

Sphincter pharyngoplasty is a comparable operation for treatment of velopharyngeal insufficiency, with a reported success rate similar to that of a pharyngeal flap (78% to 90%; Riski et al., 1992; Witt et al., 1994; James et al., 1996; Witt, Marsh, et al., 1998; Orticochea, 1999; Ysunza et al., 1999; Ysunza et al., 2002; Losken et al., 2003). Nevertheless, two prospective randomized trials have shown that a pharyngeal flap is more effective, although not statistically significantly, than a sphincter pharyngoplasty (Ysunza et al., 2002; Abyholm et al., 2005). Some complications of a sphincter pharyngoplasty are higher than a pharyngeal flap, with revision rates of 12% to 16% (Riski et al., 1992; Sie et al., 1998; Witt, Marsh, et al., 1998; Losken et al., 2003) and hyponasality in up to 22% of patients (Losken et al., 2003). The rate of obstructive sleep apnea is not different between the two procedures (Abyholm et al., 2005).

### Limitations

Whereas data collected from a single surgeon eliminates some of the variability seen in other reports, our results may not necessarily be the same for other surgeons. Furthermore, the sample size in this and most studies of SMCP prevents multivariable statistical analyses to assess the relative contributions of age of repair and operative technique. The few children operated on before 1 and 2 years of age also limited our ability to make conclusive statements about the effect of age and early palatoplasty on speech outcome. Our two-flap palatoplasty technique involved levator muscular repositioning, but these operations and those of many other reports were performed before Sommerlad (2003) espoused radical repositioning. Perhaps these patients may have benefited from more extensive levator dissection and repositioning. Nevertheless, Sommerlad, who performed a thorough multivariable analysis, reported moderate or severe hypernasality and nasal emission in 38% of his patients with SMCP (Sommerlad et al., 2004).

Another criticism of our report would be that speech outcomes were obtained from more than one speech pathologist, and interrater reliability was not evaluated. Speech pathologists may vary in their objective description of speech characteristics. We also asked all patients if their speech posed a personal or social problem. Children will describe the mockery of others at their funny voice, and

perhaps other surgeons and speech pathologists need to elicit these symptoms more often (Albery et al., 1982). Further, we evaluated the need for a secondary operation. Secondary operative incidences can be difficult to compare among surgeons and institutions because the threshold to recommend such operations is variable.

### CONCLUSIONS

We evaluated perceptual speech results and the need for a secondary operation following repair of SMCP by one of three operations (two-flap palatoplasty with muscular repositioning, double-opposing Z-palatoplasty, or pharyngeal flap) performed by one surgeon over a 24-year period. Our findings suggest a logic track for treatment of SMCP. The study showed that a secondary operation will be necessary in 70% of patients following two-flap palatoplasty, 33% following double-opposing Z-palatoplasty, and less than 10% following pharyngeal flap. Therefore, we recommend double-opposing Z-palatoplasty as the primary operation for children younger than 4 to 5 years with SMCP (overt or occult) and velopharyngeal insufficiency. For cooperative children older than 4 to 5 years who are able to undergo videofluoroscopy, a primary pharyngeal flap can be performed with high rate of success and rare complications. Nevertheless, a pharyngeal flap could also be reserved as an effective secondary operation, if double-opposing Z-palatoplasty is unsuccessful.

### REFERENCES

- Abdel-Aziz M. Treatment of submucous cleft palate by pharyngeal flap as a primary procedure. *Int J Pediatr Otorhinolaryngol.* 2007;71:1093–1097.
- Abyholm FE. Submucous cleft palate. *Scand J Plast Reconstr Surg.* 1976;10:209–212.
- Abyholm F, D'Antonio L, Davidson Ward SL, Kjoll L, Saeed M, Shaw W, Sloan G, Whitby D, Worthington H, Wyatt R. Pharyngeal flap and sphincterplasty for velopharyngeal insufficiency have equal outcome at 1 year postoperatively: results of a randomized trial. *Cleft Palate Craniofac J.* 2005;42:501–511.
- Albery EH, Bennett JA, Pigott RW, Simmons RM. The results of 100 operations for velopharyngeal incompetence—selected on the findings of endoscopic and radiological examination. *Br J Plast Surg.* 1982;35:118–126.
- Andrades P, Espinosa-de-los-Monteros A, Shell DHT, Thurston TE, Fowler JS, Xavier ST, Ray PD, Grant JH III. The importance of radical intravelar veloplasty during two-flap palatoplasty. *Plast Reconstr Surg.* 2008;122:1121–1130.
- Arvystas M, Shprintzen RJ. Craniofacial morphology in the velo-cardio-facial syndrome. *J Craniofac Genet Dev Biol.* 1984;4:39–45.
- Bardach J, Morris HL, Olin WH, Gray SD, Jones DL, Kelly KM, Shaw WC, Semb G. Results of multidisciplinary management of bilateral cleft lip and palate at the Iowa Cleft Palate Center. *Plast Reconstr Surg.* 1992;89:419–432.
- Brothers DB, Dalston RW, Peterson HD, Lawrence WT. Comparison of the Furlow double-opposing Z-palatoplasty with the Wardill-Kilner procedure for isolated clefts of the soft palate. *Plast Reconstr Surg.* 1995;95:969–977.



- Cable BB, Canady JW, Karnell MP, Karnell LH, Malick DN. Pharyngeal flap surgery: long-term outcomes at the University of Iowa. *Plast Reconstr Surg*. 2004;113:475–478.
- Calnan J. Submucous cleft palate. *Br J Plast Surg*. 1954;6:264–282.
- Canady JW, Cable BB, Karnell MP, Karnell LH. Pharyngeal flap surgery: protocols, complications, and outcomes at the University of Iowa. *Otolaryngol Head Neck Surg*. 2003;129:321–326.
- Chapman KL, Hardin-Jones MA, Goldstein JA, Halter KA, Havlik RJ, Schulte J. Timing of palatal surgery and speech outcome. *Cleft Palate Craniofac J*. 2008;45:297–308.
- Chegar BE, Shprintzen RJ, Curtis MS, Tatum SA. Pharyngeal flap and obstructive apnea: maximizing speech outcome while limiting complications. *Arch Facial Plast Surg*. 2007;9:252–259.
- Chen KT, Wu J, Noordhoff SM. Submucous cleft palate. *Changcheng Yi Xue Za Zhi*. 1994;17:131–137.
- Chen PK, Wu J, Hung KF, Chen YR, Noordhoff MS. Surgical correction of submucous cleft palate with Furlow palatoplasty. *Plast Reconstr Surg*. 1996;97:1136–1146.
- Crikelair GF, Striker P, Cosman B. The surgical treatment of submucous cleft palate. *Plast Reconstr Surg*. 1970;45:58–65.
- D'Antonio LL, Eichenberg BJ, Zimmerman GJ, Patel S, Riski JE, Herber SC, Hardesty RA. Radiographic and aerodynamic measures of velopharyngeal anatomy and function following Furlow Z-plasty. *Plast Reconstr Surg*. 2000;106:539–549.
- Dailey SA, Karnell MP, Karnell LH, Canady JW. Comparison of resonance outcomes after pharyngeal flap and furlow double-opposing z-plasty for surgical management of velopharyngeal incompetence. *Cleft Palate Craniofac J*. 2006;43:38–43.
- David DJ, Anderson PJ, Schnitt DE, Nugent MA, Sells R. From birth to maturity: a group of patients who have completed their protocol management. Part II. Isolated cleft palate. *Plast Reconstr Surg*. 2006;117:515–526.
- Dorf DS, Curtin JW. Early cleft palate repair and speech outcome. *Plast Reconstr Surg*. 1982;70:74–81.
- Ford LC, Sulprizio SL, Rasgon BM. Otolaryngological manifestations of velocardiofacial syndrome: a retrospective review of 35 patients. *Laryngoscope*. 2000;110:362–367.
- Furlow LT Jr. Cleft palate repair by double opposing Z-plasty. *Plast Reconstr Surg*. 1986;78:724–738.
- Garcia Velasco M, Ysunza A, Hernandez X, Marquez C. Diagnosis and treatment of submucous cleft palate: a review of 108 cases. *Cleft Palate J*. 1988;25:171–173.
- Goldberg R, Motzkin B, Marion R, Scambler PJ, Shprintzen RJ. Velocardio-facial syndrome: a review of 120 patients. *Am J Med Genet*. 1993;45:313–319.
- Gosain AK, Conley SF, Marks S, Larson DL. Submucous cleft palate: diagnostic methods and outcomes of surgical treatment. *Plast Reconstr Surg*. 1996;97:1497–1509.
- Gunther E, Wisser JR, Cohen MA, Brown AS. Palatoplasty: Furlow's double reversing Z-plasty versus intravelar veloplasty. *Cleft Palate Craniofac J*. 1998;35:546–549.
- Hofer SO, Dhar BK, Robinson PH, Goorhuis-Brouwer SM, Nicolai JP. A 10-year review of perioperative complications in pharyngeal flap surgery. *Plast Reconstr Surg*. 2002;110:1393–1397.
- Hogan VM. A clarification of the surgical goals in cleft palate speech and the introduction of the lateral port control (l.p.c.) pharyngeal flap. *Cleft Palate J*. 1973;10:331–345.
- Hoopes JE, Dellon AL, Fabrikant JI, Soliman AH. Cineradiographic assessment of combined island flap pushback and pharyngeal flap in the surgical management of submucous cleft palate. *Br J Plast Surg*. 1970;23:39–44.
- Husein M, Chang E, Cable B, Karnell M, Karnell LH, Canady JW. Outcomes for children with submucous cleft palate and velopharyngeal insufficiency. *J Otolaryngol*. 2004;33:222–226.
- Inman DS, Thomas P, Hodgkinson PD, Reid CA. Oro-nasal fistula development and velopharyngeal insufficiency following primary cleft palate surgery—an audit of 148 children born between 1985 and 1997. *Br J Plast Surg*. 2005;58:1051–1054.
- Isotalo E, Pulkkinen J, Haapanen ML. Speech in 6 year old children with sub-mucous cleft palate. *J Craniofac Surg*. 2007;18:717–722.
- Isotalo E, Pulkkinen J, Haapanen ML. Correspondence: speech in 6-year-old children with submucous cleft palate. *J Craniofac Surg*. 2008;19:869–870.
- James NK, Twist M, Turner MM, Milward TM. An audit of velopharyngeal incompetence treated by the orticochea pharyngoplasty. *Br J Plast Surg*. 1996;49:197–201.
- Kaplan EN. The occult submucous cleft palate. *Cleft Palate J*. 1975;12:356–368.
- Kelly AB. Congenital insufficiency of the palate. *J Laryngol Rhinol Otol*. 1910;25:281–300.
- Kirschner RE, Wang P, Jawad AF, Duran M, Cohen M, Solot C, Randall P, LaRossa D. Cleft-palate repair by modified Furlow double-opposing Z-plasty: the Children's Hospital of Philadelphia experience. *Plast Reconstr Surg*. 1999;104:1998–2010.
- Lam E, Hundert S, Wilkes GH. Lateral pharyngeal wall and velar movement and tailoring velopharyngeal surgery: determinants of velopharyngeal incompetence resolution in patients with cleft palate. *Plast Reconstr Surg*. 2007;120:495–505.
- LaRossa D, Jackson OH, Kirschner RE, Low DW, Solot CB, Cohen MA, Mayro R, Wang P, Minugh-Purvis N, Randall P. The Children's Hospital of Philadelphia modification of the Furlow double-opposing z-palatoplasty: long-term speech and growth results. *Clin Plast Surg*. 2004;31:243–249.
- Lewin ML. Occult submucous cleft palate. *Cleft Palate J*. 1984;21:41–42.
- Lewin ML, Croft CB, Shprintzen RJ. Velopharyngeal insufficiency due to hypoplasia of the musculus uvulae and occult submucous cleft palate. *Plast Reconstr Surg*. 1980;65:585–591.
- Lindsey WH, Davis PT. Correction of velopharyngeal insufficiency with Furlow palatoplasty. *Arch Otolaryngol Head Neck Surg*. 1996;122:881–884.
- Losken A, Williams JK, Burstein FD, Malick D, Riski JE. An outcome evaluation of sphincter pharyngoplasty for the management of velopharyngeal insufficiency. *Plast Reconstr Surg*. 2003;112:1755–1761.
- Marrinan EM, LaBrie RA, Mulliken JB. Velopharyngeal function in nonsyndromic cleft palate: relevance of surgical technique, age at repair, and cleft type. *Cleft Palate Craniofac J*. 1998;35:95–100.
- McWilliams BJ. Submucous clefts of the palate: how likely are they to be symptomatic? *Cleft Palate Craniofac J*. 1991;28:247–249.
- McWilliams BJ, Philips BJ. *Velopharyngeal Incompetence: Audio Seminars in Speech Pathology*. Philadelphia: WB Saunders; 1979.
- Mendoza M, Molina F, Azzolini C, Ysunza Rivera A. Minimal incision palatopharyngoplasty: a preliminary report. *Scand J Plast Reconstr Surg Hand Surg*. 1994;28:199–205.
- Minami T, Kaplan EN, Wu G, Jobe RP. Velopharyngeal incompetence without overt cleft palate: a collective review and experience with 98 patients. *Plast Reconstr Surg*. 1975;55:573–587.
- Morris HL, Bardach J, Jones D, Christiansen JL, Gray SD. Clinical results of pharyngeal flap surgery: the Iowa experience. *Plast Reconstr Surg*. 1995;95:652–662.
- Orticochea M. The timing and management of dynamic muscular pharyngeal sphincter construction in velopharyngeal incompetence. *Br J Plast Surg*. 1999;52:85–87.
- Park S, Saso Y, Ito O, Tokioka K, Kato K, Nitta N, Kitano I. A retrospective study of speech development in patients with submucous cleft palate treated by four operations. *Scand J Plast Reconstr Surg Hand Surg*. 2000;34:131–136.
- Pensler JM, Bauer BS. Levator repositioning and palatal lengthening for submucous clefts. *Plast Reconstr Surg*. 1988;82:765–769.
- Perkins JA, Lewis CW, Gruss JS, Eblen LE, Sie KC. Furlow palatoplasty for management of velopharyngeal insufficiency: a prospective study of 148 consecutive patients. *Plast Reconstr Surg*. 2005;116:72–80.

- Porterfield HW, Mohler LR, Sandel A. Submucous cleft palate. *Plast Reconstr Surg.* 1976;58:60–65.
- Porterfield HW, Traube JC. Submucous cleft palate. *Plast Reconstr Surg.* 1965;35:45–50.
- Riski JE, Ruff GL, Georgiade GS, Barwick WJ, Edwards PD. Evaluation of the sphincter pharyngoplasty. *Cleft Palate Craniofac J.* 1992;29:254–261.
- Rohrich RJ, Love EJ, Byrd HS, Johns DF. Optimal timing of cleft palate closure. *Plast Reconstr Surg.* 2000;106:413–421.
- Roux PJ. *Mémoire sur la staphylorrhaphie, ou suture du voile du palais.* Paris: J.S. Chaudé; 1825.
- Salzer KE, Sng KW, Sperry EE. Two-flap palatoplasty: 20-year experience and evolution of surgical technique. *Plast Reconstr Surg.* 2006;118:193–204.
- Scheuerle J, Habal MB. Discussion of Isotalo et al.: speech in 6-year-old children with submucous cleft palate. *J Craniofac Surg.* 2007;19:723–724.
- Seagle MB, Patti CS, Williams WN, Wood VD. Submucous cleft palate: a 10-year series. *Ann Plast Surg.* 1999;42:142–148.
- Seyfer AE, Prohazka D, Leahy E. The effectiveness of the superiorly based pharyngeal flap in relation to the type of palatal defect and timing of the operation. *Plast Reconstr Surg.* 1988;82:760–764.
- Seyfer AE, Simon CD. Long-term results following the repair of palatal clefts: a comparison of three different techniques. *Plast Reconstr Surg.* 1989;83:785–790.
- Shprintzen RJ, Golding-Kushner KJ. Evaluation of velopharyngeal insufficiency. *Otolaryngol Clin North Am.* 1989;22:519–536.
- Shprintzen RJ, Lewin ML, Croft CB, Daniller AI, Argamaso RV, Ship AG, Strauch B. A comprehensive study of pharyngeal flap surgery: tailor made flaps. *Cleft Palate J.* 1979;16:46–55.
- Shprintzen RJ, Schwartz RH, Daniller A, Hoch L. Morphologic significance of bifid uvula. *Pediatrics.* 1985;75:553–561.
- Sie KC, Gruss JS. Results with Furlow palatoplasty in the management of velopharyngeal insufficiency. *Plast Reconstr Surg.* 2002;109:2588–2589.
- Sie KC, Tampakopoulou DA, de Serres LM, Gruss JS, Eblen LE, Yonick T. Sphincter pharyngoplasty: speech outcome and complications. *Laryngoscope.* 1998;108:1211–1217.
- Sloan GM. Posterior pharyngeal flap and sphincter pharyngoplasty: the state of the art. *Cleft Palate Craniofac J.* 2000;37:112–122.
- Smith B, Guyette TW. Evaluation of cleft palate speech. *Clin Plast Surg.* 2004;31:251–260, ix.
- Sommerlad BC. A technique for cleft palate repair. *Plast Reconstr Surg.* 2003;112:1542–1548.
- Sommerlad BC, Fenn C, Harland K, Sell D, Birch MJ, Dave R, Lees M, Barnett A. Submucous cleft palate: a grading system and review of 40 consecutive submucous cleft palate repairs. *Cleft Palate Craniofac J.* 2004;41:114–123.
- Sullivan SR, Murrinan EM, Labrie RA, Rogers GF, Mulliken JB. Palatoplasty outcomes in nonsyndromic patients with cleft palate: a 29-year assessment of one surgeon's experience. *J Craniofac Surg.* 2009;20:612–616.
- Sullivan SR, Murrinan EM, Mulliken JB. Pharyngeal flap outcomes in non-syndromic children with repaired cleft palate and velopharyngeal insufficiency. *Plast Reconstr Surg.* 2010;125:290–298.
- Trost JE. Articulatory additions to the classical description of the speech of persons with cleft palate. *Cleft Palate J.* 1981;18:193–203.
- Weatherley-White RC, Sakura CY Jr, Brenner LD, Stewart JM, Ott JE. Submucous cleft palate: its incidence, natural history, and indications for treatment. *Plast Reconstr Surg.* 1972;49:297–304.
- Williams MA, Shprintzen RJ, Rakoff SJ. Adenoid hypoplasia in the velocardio-facial syndrome. *J Craniofac Genet Dev Biol.* 1987;7:23–26.
- Witt PD, D'Antonio LL, Zimmerman GJ, Marsh JL. Sphincter pharyngoplasty: a preoperative and postoperative analysis of perceptual speech characteristics and endoscopic studies of velopharyngeal function. *Plast Reconstr Surg.* 1994;93:1154–1168.
- Witt PD, Marsh JL, Arlis H, Grames LM, Ellis RA, Pilgram TK. Quantification of dynamic velopharyngeal port excursion following sphincter pharyngoplasty. *Plast Reconstr Surg.* 1998;101:1205–1211.
- Witt PD, Wahlen JC, Marsh JL, Grames LM, Pilgram TK. The effect of surgeon experience on velopharyngeal functional outcome following palatoplasty: is there a learning curve? *Plast Reconstr Surg.* 1998;102:1375–1384.
- Ysunza A, Garcia-Velasco M, Garcia-Garcia M, Haro R, Valencia M. Obstructive sleep apnea secondary to surgery for velopharyngeal insufficiency. *Cleft Palate Craniofac J.* 1993;30:387–390.
- Ysunza A, Pamplona MC, Mendoza M, Molina F, Martinez P, Garcia-Velasco M, Prada N. Surgical treatment of submucous cleft palate: a comparative trial of two modalities for palatal closure. *Plast Reconstr Surg.* 2001;107:9–14.
- Ysunza A, Pamplona MC, Molina F, Chacon E, Collado M. Velopharyngeal motion after sphincter pharyngoplasty: a videonasopharyngoscopic and electromyographic study. *Plast Reconstr Surg.* 1999;104:905–910.
- Ysunza A, Pamplona C, Ramirez E, Molina F, Mendoza M, Silva A. Velopharyngeal surgery: a prospective randomized study of pharyngeal flaps and sphincter pharyngoplasties. *Plast Reconstr Surg.* 2002;110:1401–1407.