

# PARADIGM SHIFTS IN ORTHODONTICS AND ORTHOGNATHIC SURGERY

Dr Sivabalan Vasudavan, BSc, MDSc, MPH, MOrth, RCS, MRACDS (Ortho), FDSRCS

*Dr Sivabalan Vasudavan is a Specialist Orthodontist in Claremont, Western Australia.*

## ABSTRACT

The orthodontic specialty has observed a significant paradigm shift in the delivery of orthodontic care, as evolving technological advances have been incorporated into specialist practice. However, particular attention to sound biomechanical design and treatment planning principles continue to underpin the successful resolution of many presenting malocclusions. Practitioners must be able to distinguish between marketing hyperbole and the utility available for their patient.

The orthodontic profession is being split between 'appliance-drive fast-food orthodontics' where the results to a large extent are dependent on both growth and function and 'orthodontist-driven slow-food: treatments attempt' to push the limits of the possible in relation to complicated problems and reversal of degeneration of adult patients. The latter treatment is performed with individualized appliances adapting the specific force system to the patient.

Orthodontists work towards establishing a comprehensive diagnosis and synthesis of the pertinent issues for each patient. Individualized treatment objectives are then established which leads to the formulation of a biomechanical plan and ordered treatment sequence. Orthodontic treatment is performed and outcomes can be objectively evaluated at completion. A prioritized problem list establishes an ordinal sequence of the issues that require to be addressed. Specific treatment objectives are established that address facial, skeletal, dental and biological needs. The biomechanical plan can consist of an exclusive orthodontic approach or include adjunctive surgical procedures.

Pure orthodontic treatment planning, which does not include orthopaedic and functional aspects, should include the following stages:

- Definition of a three-dimensional treatment objective
- Definition of the necessary force systems to displace active units
- General anchorage evaluation
- Subdivision of treatment in stages
- Selection and design of the orthodontic appliance for each stage

The SureSmile® system (Orametrix, Richardson TX) was developed in the early 2000s and was intended to overcome the potential problems associated with statistically indeterminate mechanics commonly associated with conventional straightwire systems including manual wire bending, bracket placement, variations in surface tooth morphology, and the lack of control when using clear aligners. Utilizing highly accurate robots to custom bend archwires for each patient, the SureSmile® system attempted to circumvent the problems encountered in the past that include the difficulty in achieving accurate finishing bends, and ideal final occlusions.<sup>1</sup> The SureSmile® system now encompasses the facilities for the designation of virtual bracket positioning and tooth movement, and the concomitant rapid prototyping of indirect bonding trays and aligner systems.

SureSmile® provides an integrated digital technology platform that enables clinicians to diagnose, plan, and design a customized therapeutic solution in the form of a prescription archwire for the patient. SureSmile®'s 3D-imaging environment allows for improved spatial visualization, localization, and measurement of the dentition in all three planes of space. Bouwens et al.<sup>2</sup> noted a significant difference between root angulation measurements from panoramic and 3D cone beam computed tomography (CBCT) images.

SureSmile® provides a robust, interactive decision support system driven by simulations. Through simulations, a clinician can visualize and validate the mental model of a plan with regard to treatment position. Furthermore, the treatment plan can be designed interactively with the patient. Almog et al.<sup>3</sup> demonstrated that computer-imaging simulations provide patients with a better understanding of proposed treatment plans. The SureSmile® decision support system also allows for interprofessional collaboration since clinicians share their treatment plans with and seek clinical advice from one another. Both patient-clinician and interprofessional collaboration may minimize the disconnection in treatment objectives.

SureSmile® software has built-in workflow automation and standardized checklists that provide a framework for the sequential management of patient care. Wolff et al.<sup>4</sup> showed that the incorporation of checklists in clinical pathways results in improvements in the quality of patient care and builds reliability.

The use of conventional appliances largely requires iterative changes to bracket position coupled with archwire bends, which prolongs care. Studies on the reliability of conventional straight-wire appliances reveal that bracket slots have relatively poor tolerances, which may lead to imprecise tooth movement and add to treatment time. Conversely, a predefined plan drives the design of the SureSmile® customized prescription archwire. The angular and torsional bends of the robotically bent archwire are precise to  $\pm 1$  degree and linear bends are precise to  $\pm 0.1$ mm. The coupling of the clinician's plan and the prescription archwire overcomes the reactive elements of orthodontic care and enhances the reliability of appliance design. The movement of the dentition is more directed, potentially resulting in a shorter care cycle.

SureSmile® technology in itself is not a panacea. It is only an enabling technology. Successful treatment outcomes can only be achieved in a timely manner when care is driven by an expert who has accumulated experience through deliberate practice. Visual light scans resulting in digital dental models of the patient's dentition after the leveling and aligning procedure allowed the provider to treatment plan each

patient digitally. These customized appliance systems combine the precision of the pre-adjusted brackets and computer fabrication with the versatility and customization of manual wire bending, resulting in a treatment system that is individualized to each patient.

Without the development of digital models many of the customized orthodontic appliance systems would be impossible. The first of these appliances was the Invisalign® system (Align Technology, San Jose CA), where clear aligners are custom fabricated to move teeth slowly. Invisalign® uses computer modelling to design and manufacture its aligners. The ClinCheck® software was developed by Align Technology to give the practitioner a preview of the prescribed tooth movements so that they can make any changes, as needed, before the aligners are fabricated.

CAD-CAM technology was the first technology that allowed the doctor to see the intended finish before starting the treatment. However, it has been shown that the Invisalign® system is not as precise as using traditional orthodontic brackets for correcting large anteroposterior discrepancies and results in less than ideal occlusal contact.<sup>5</sup> Invisalign® is inaccurate in several movements, especially extrusion and the rotation of round teeth.<sup>6,7</sup> Align Technology has attempted to correct the flaws with the system by developing new attachments that they claim are more effective in producing the prescribed movements. In order to address the issues of inaccuracy, Orametrix, Inc. developed the SureSmile® system. The system allows orthodontists to use their choice of bracket, and integrates digital treatment planning with highly accurate, robotically bent custom archwires.

Much like the Invisalign® system, a digital diagnostic setup (termed the “plan” by SureSmile®) of the anticipated final occlusion is necessary with the SureSmile® system. In contrast to previous iterations of the Invisalign® Clincheck treatment simulation platform, SureSmile® allows the clinician to modify the predicted tooth positions directly. Once approved by the clinician, a robot bends the wires from the doctor's choice of several materials, including copper-nickel-titanium alloy, beta-titanium alloy, and Elgiloy™<sup>8,9</sup>. According to SureSmile®, approximately 80-90% of the wires bent are copper-nickel-titanium.

SureSmile® claims that because the system is so accurate and round tripping is eliminated, the finished result is superior and completed more quickly than traditional pre-adjusted orthodontic treatment. The SureSmile® system allows compensation for the bracket choice and final wire size, in that each orthodontist has a preference as to the bracket system they use, and many never use a full sized archwire.<sup>1</sup> The ability to place compensatory bends in the arch wire allow precise tooth positions to be attained without having to use heavy, full-sized archwires.

Recently, several studies have investigated the SureSmile® system. The first, a study by Saxe and coworkers, indicated that using this system was more efficient than traditional orthodontic appliances.<sup>10</sup> Patients finished, on average, in six fewer months when treated with the SureSmile® system. In addition, those patients treated with SureSmile® had statistically lower CRE scores than those treated with conventional means. There were a limited number of patients from three providers included in the study by Saxe et al.<sup>10</sup> and the demographics of the treatment groups were not disclosed. Furthermore, parametric statistical analyses were incorrectly used. Due to the ordinal nature of the ABO grading system nonparametric statistics are appropriate.

Until very recently, no fully independent study had been conducted investigating both the efficiency and quality of treatment rendered using the SureSmile® system. The study published by Alford et al.<sup>11</sup> concluded that patients treated with SureSmile® finished more quickly and had improved alignment and rotations and interproximal contacts when using the CRE criteria, when compared to conventional pre-adjusted orthodontic patients. Interestingly, Alford and co-workers<sup>11</sup> also found that the root alignment in the conventional group to be superior to the SureSmile® group. They hypothesized that the robot-bent .019” x .025” copper-nickel-titanium wire that many SureSmile® providers use to finish their cases is not strong enough to upright the roots effectively. Their data sample did not include any patients who had Cone Beam Computer Tomography (CBCT) scans, which serves to model the initial root morphology more accurately. Additionally, there is availability for practitioners to elect to use different archwire materials including i) Beta Titanium (commercially available as Titanium Molybdenum Alloy (TMA)) which has a modulus of elasticity approximately twice that of Nickel Titanium, ii) and Chrome Cobalt Alloys (commercially available as Elgiloy.) It is difficult to extract meaningful conclusions from the study, as the average DI of the SureSmile® group was statistically lower than that of the conventional group, and the demographics of each group were not disclosed. As new technologies emerge, it is imperative that proper research be conducted to evaluate their efficacy.

Sachdeva et al.<sup>9</sup> audited the first 12, 335 completed patient histories from the OraMetric database, Comparative Effectiveness Research Program (CERP), and attempted to determine the efficiency of SureSmile® vs conventional treatment in terms of treatment time and additional variables that influence treatment time. The following statistically significant ( $P < 0.001$ ) conclusions were made:

- SureSmile® patients experienced a median treatment time of 15 months, which is 8 months less than that of conventional patients (23 months).
- SureSmile® patients experienced a median treatment visitation period of 14 visits, which is a period of four fewer visits than that of conventional patients (18 visits).
- Class I, II, and III SureSmile® patients experienced care cycles 8 to 9 months shorter than those of Class I, II, and III conventional patients.
- Class II SureSmile® patients experienced shorter cycles than Class I SureSmile® patients, and Class III SureSmile® patients experienced the longest care cycles in the SureSmile® patient group.
- SureSmile® adolescents and adults did not experience statistically significant difference in treatment time.

A combined orthodontic and orthognathic approach is routinely used to produce aesthetically and functionally superior treatment results in patients presenting with significant dentofacial deformities. A successful surgical outcome is determined by the correction of skeletal and dental abnormalities leading to an aesthetic improvement and facial soft tissue harmony as judged by both patients and practitioners.

Surgical movements of the skeleton can influence the overlying soft tissue dimensions and these factors must be taken into consideration during orthognathic planning. Complex congenital, developmental, and acquired deformities of the facial skeleton are managed by re-establishing the facial symmetry and projection through restoration of the maxillomandibular relationships. Computer planning systems have been developed for use in the craniofacial skeleton and provide individualized, 3-dimensional manipulation of CT Dicom data sets. Numerous CAD/CAM (Computer Aided Design/Computer Aided Manufacturing) programs are commercially available in orthognathic surgery.

De Riu et al.<sup>13</sup> conducted a randomized clinical trial with 20 subjects, to determine the accuracy of computer assisted orthognathic surgical planning versus conventional surgical planning in the correction of facial asymmetry. Specifically, the objective of this study was to measure and compare the rates of alignment and reduction of cant of the dental and facial midlines between the two groups. The investigators found differences between the two groups in the alignment of the lower inter-incisal point ( $p = 0.03$ ), mandibular sagittal plane ( $p = 0.01$ ), and centering of the dental midlines ( $p = 0.03$ ) which were significant, with the digital planning group being more accurate.<sup>13</sup>

Centenero and Hernandez-Alfaro<sup>14</sup> conducted a cross-over study to assess the superiority of intra-operative accuracy of intermediate surgical splints produced by a CAD/CAM technology over conventionally produced surgical splints across 16 subjects. There was a high degree of correlation in 15 of the 16 cases. Furthermore, there was a high coefficient of correlation in the majority of predictions of results in hard tissue, although less precise results were obtained in measurements in the soft tissue in the labial area.

Plooij et al.<sup>15</sup> conducted a systematic review of fifteen articles describing 3D digital image fusion models of two or more different imaging techniques for orthodontics and orthognathic surgery, and concluded that image fusion and especially the 3D virtual head are accurate and realistic tools for documentation, analysis, treatment planning and long-term follow-up.

Marchetti et al.<sup>16</sup> conducted an investigation to validate the computer imaging software, SurgiCase-CMF® Materialise, that enables surgeons to perform virtual orthognathic surgical planning using a three dimensional (3D) utility that previews the final shape of hard and soft tissues. A soft tissue simulation module creates images of soft tissue altered through bimaxillary orthognathic surgery to correct facial deformities, using a CT Dicom-based treatment simulation platform. The software rapidly follows clinical options to generate a series of simulations and soft tissue models. Comparing simulation results with postoperative CT data, the reliability of the soft tissue preview was > 91%.

Two patients are presented that underwent coordinated surgical-orthodontic care, utilizing a virtual surgical planning approach with SimPlant OMS (Materialise). Physical examination was performed and anthropometric measurements were obtained and analysed. Cone Beam CT scan data was obtained for each patient. Digital clinical photographs, maxillary and mandibular stone casts, clinical anthropometric measurements, and data from natural head position readings and final occlusion registration was electronically remitted to a software engineer for computer rendering (Medical Modelling, Golden, Colorado, USA).

### Case 1

A fit and healthy 28 year female presented with an Angle Class II Division I malocclusion, increased facial convexity secondary to mandibular retrognathia, an anterior openbite with dual occlusal planes in the maxilla, and an anterior diastema. An increased overjet relationship was noted. A vertical maxillary excess was noted, with a concomitant narrow maxillary arch, and bilateral TMJ clicking.

The coordinated surgical plan included a segmental Le Fort I maxillary osteotomy with a maxillary advancement of 2mm, differential impaction with anterior superior repositioning of 1mm and posterior superior repositioning of 2mm, and rotation of the maxillary midline to the left by 0.5 mm. Interdental osteotomies were performed between teeth 13 and 14, and teeth 23 and 24. The maxilla was fixed with mini-plates and mini-screws and bone grafting was performed at the Le Fort I level and an alar base cinch suture was placed to control the nasal tip relationships. Bilateral sagittal split osteotomies (BSSO) of the mandible were performed with advancement of 5.5 mm and rigid fixation with mini-plates and mini-screws. A sliding augmentation genioplasty of 4 mm was performed, with anterior down-grafting of 1 mm, and secured with rigid fixation with mini-screws.

Full fixed appliances were removed approximately four months following the bimaxillary orthognathic surgery procedure. Improvements in the patient's facial aesthetics, symmetry, balance and occlusion were noted (Figures 1- 7).

### Case 2

A 23 years 10 month old healthy and fit female presented with a chief concern about her facial convexity, excessive gingival display and recessive chin. She reported a previous history of full fixed orthodontic treatment as an adolescent with the adjunctive use of a rapid maxillary expansion appliance. The patient presented with an Angle Class II Division I with vertical maxillary excess, maxillary and mandibular retrognathia, maxillary constriction, anterior openbite, convex facial profile, increased overjet, and increased lower anterior facial height relationships. The patient had a prominent nose with a dorsal hump, an obtuse nasolabial angle, and lip incompetence. An anterior vertical maxillary excess was noted, with increased maxillary gingival display.

The coordinated surgical plan included a Le Fort I maxillary osteotomy with a maxillary advancement of 5 mm, differential impaction with anterior superior repositioning of 6 mm and posterior inferior repositioning of 2 mm, and expansion of the maxilla. The maxilla was fixed with mini-plates and mini-screws and bone grafting was performed at the Le Fort I level and an alar base cinch suture was placed to control the nasal tip relationships. Bilateral sagittal split osteotomies (BSSO) of the mandible were performed with advancement of 11.5 mm and rigid fixation with mini-plates and mini-screws. A sliding augmentation genioplasty of 4 mm was performed with a vertical reduction of 2 mm, and secured with rigid fixation with mini-screws.

Approximately six weeks following the orthognathic procedure, an intra-oral scan with a TRIOS scanner was obtained. A series of customized SureSmile wires were produced including 17x25 Copper Nickel Titanium, 19x25 Copper Nickel Titanium, and 19x25 Beta Titanium (TMA). The post-surgical orthodontic period was approximately eight months (Figures 8-14).

**Acknowledgement:** The author would like to express sincere gratitude and professional appreciation to Dr. Brent P. Allan, Specialist Oral and Maxillofacial Surgeon, for the provision of the coordinated orthognathic surgical care for the patients presented within this article.

## REFERENCES

1. Sachdeva RC. SureSmile technology in a patient-centered orthodontic practice. *J Clin Orthod* 2001;35:245-253.
2. Bouwens, Daniel G., et al. "Comparison of mesiodistal root angulation with posttreatment panoramic radiographs and cone-beam computed tomography." *American Journal of Orthodontics and Dentofacial Orthopedics* 2011; 139:126-132.
3. Almog D, MARIN CS, PROSKIN HM, COHEN MJ, KYRKANIDES S, MALMSTROM H. The effect of esthetic consultation methods on acceptance of diastema-closure treatment plan: a pilot study. *The Journal of the American Dental Association* 2004;135(7):875-81.
4. Wolff AM, Taylor SA, McCabe JF. Using checklists and reminders in clinical pathways to improve hospital inpatient care. *Medical Journal of Australia* 2004;181:428-31.
5. Djeu G, Shelton C, Maganzini A. Outcome assessment of Invisalign and traditional orthodontic treatment compared with the American Board of Orthodontics objective grading system. *Am J Orthod Dentofacial Orthop* 2005;128:292-298; discussion 298.
6. Alcan T, Ceylanoglu C, Baysal B. The relationship between digital model accuracy and time-dependent deformation of alginate impressions. *Angle Orthod* 2009;79:30-36.
7. Kravitz ND, Kusnoto B, BeGole E, Obrez A, Agran B. How well does Invisalign work? A prospective clinical study evaluating the efficacy of tooth movement with Invisalign. *Am J Orthod Dentofacial Orthop* 2009;135:27-35.
8. Mah J, Sachdeva R. Computer-assisted orthodontic treatment: the SureSmile process. *Am J Orthod Dentofacial Orthop* 2001;120:85-87.
9. Sachdeva R. SureSmile: technology-driven solution for orthodontics. *Tex Dent J* 2002;119:608-615.
10. Saxe AK, Louie LJ, Mah J. Efficiency and effectiveness of suresmile. *World J Orthod* 2010;11:16-22.
11. Alford TJ, Roberts WE, Hartsfield JK, Eckert GJ, Snyder RJ. Clinical outcomes for patients finished with the SureSmile method compared with conventional fixed orthodontic therapy. *Angle Orthod* 2011;81:383-388.
12. Sachdeva RCL, Aranha SLT, Egan ME et al. Treatment Time: SureSmile vs Conventional. *Orthodontics (Chic)* 2012; 13:72-85.
13. De Riu G, Meloni SM, Baj A, Corda A, Soma D, Tullio A. Computer assisted orthognathic surgery for correction of facial asymmetry: results of a randomised controlled clinical trial. *Br J Oral Maxillofac Surg* 2014;52:251-7.
14. Aboul-Hosn Centenero S, Hernandez-Alfaro F. 3D planning in orthognathic surgery: CAD/CAM surgical splints and prediction of the soft and hard tissues results—our experience in 16 cases. *J Craniomaxillofac Surg* 2012;40:162-8.
15. Plooi J.M., Maal T. J.J., Haers P. et al. Digital three-dimensional image fusion processes for planning and evaluating orthodontics and orthognathic surgery: A systematic review. *Int. J. Oral Maxillofac. Surg.* 2011; 40:341-352.
16. Marchetti C., Bianchi A., Muyldermans L., et al. Validation of new soft tissue software in orthognathic surgery planning. *Int. J. Oral Maxillofac. Surg.* 2011; 40:26-32.

**Email address for correspondence:**

[drsiva@smilewithconfidence.com.au](mailto:drsiva@smilewithconfidence.com.au)

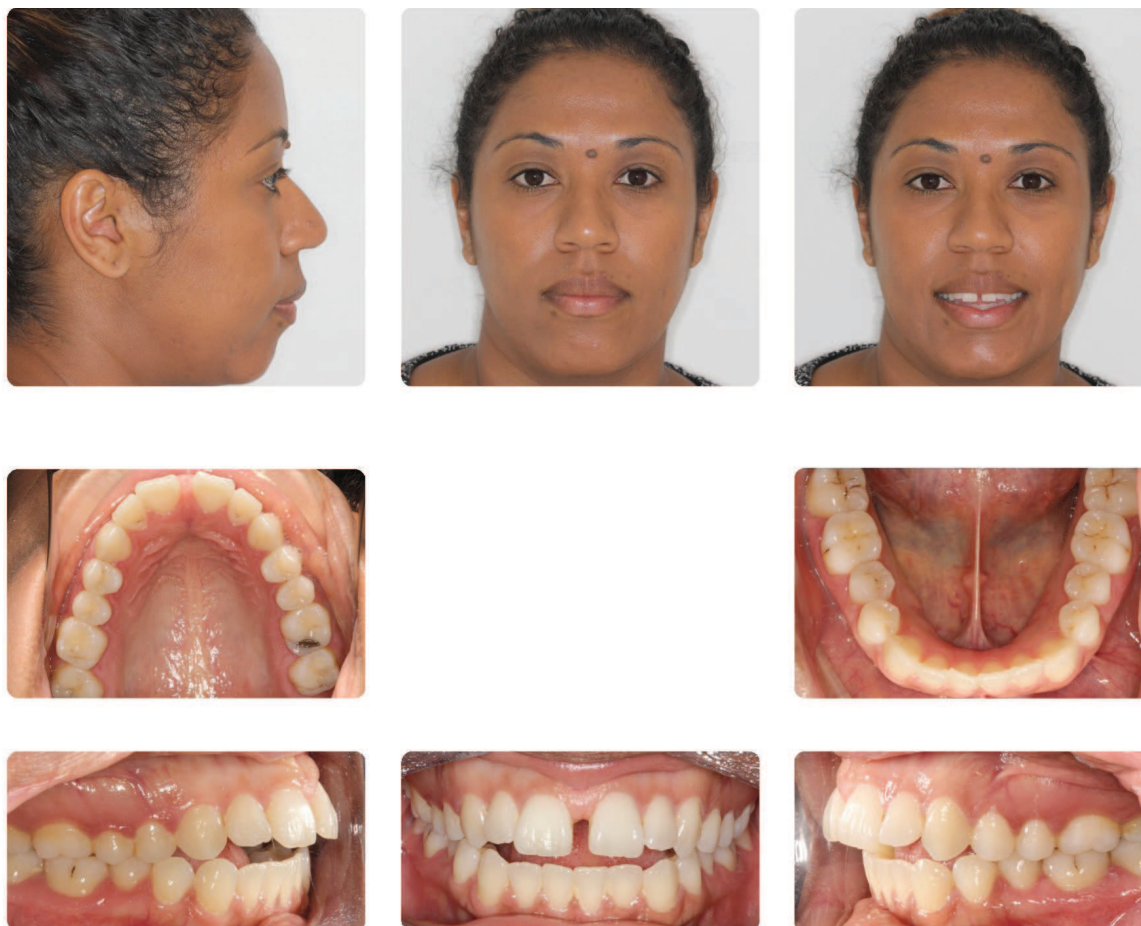

Figure 1



### Preoperative Position

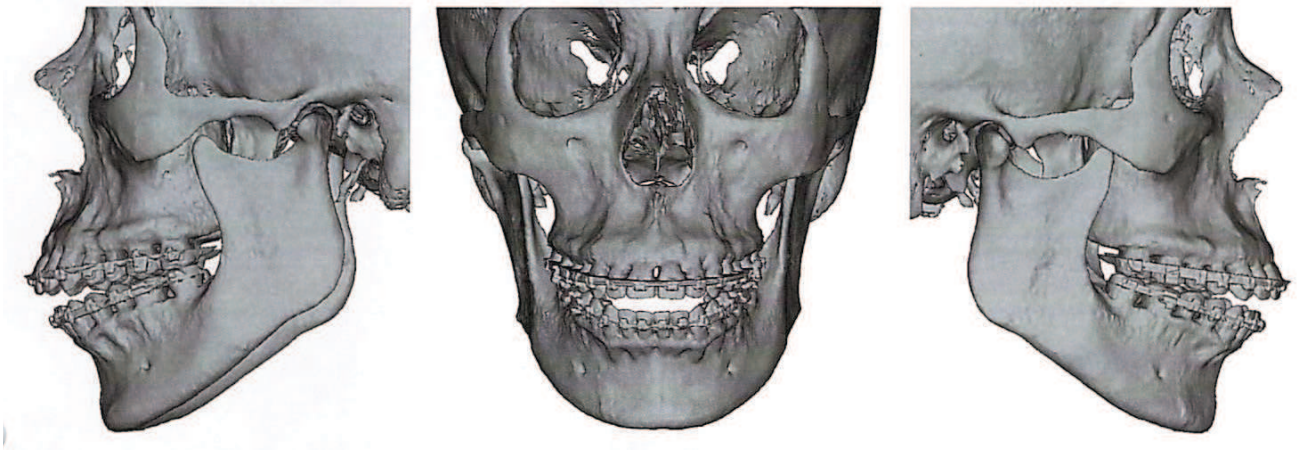

Figure 2

### Intermediate Position

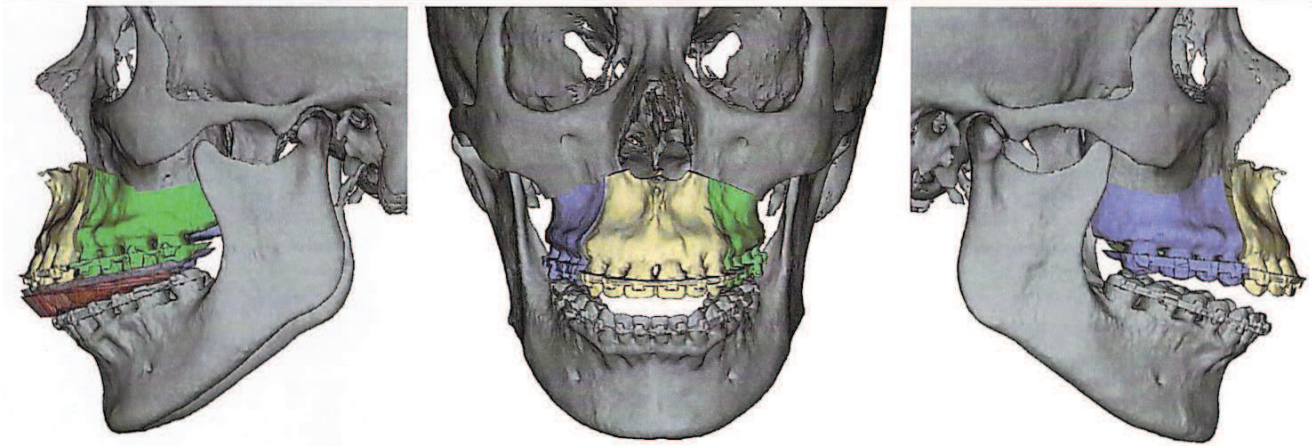


Figure 3

### Simulated Virtual Surgical Plan

**Simulated Surgical Procedure:** Segmental LeFort I, BSSO, and Genioplasty

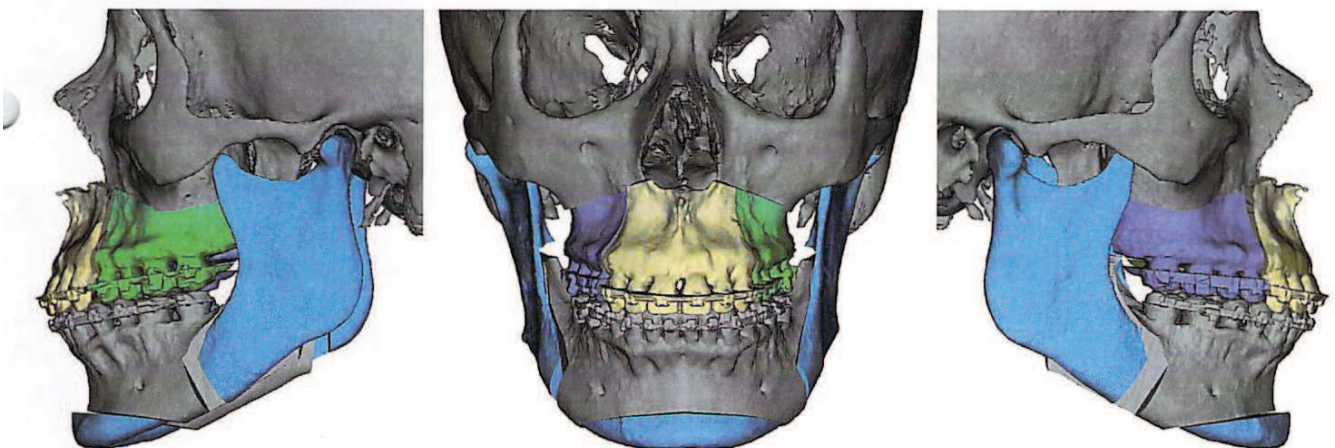


Figure 4



*Preoperative Position*




Figure 5

*Final Position*




Figure 6

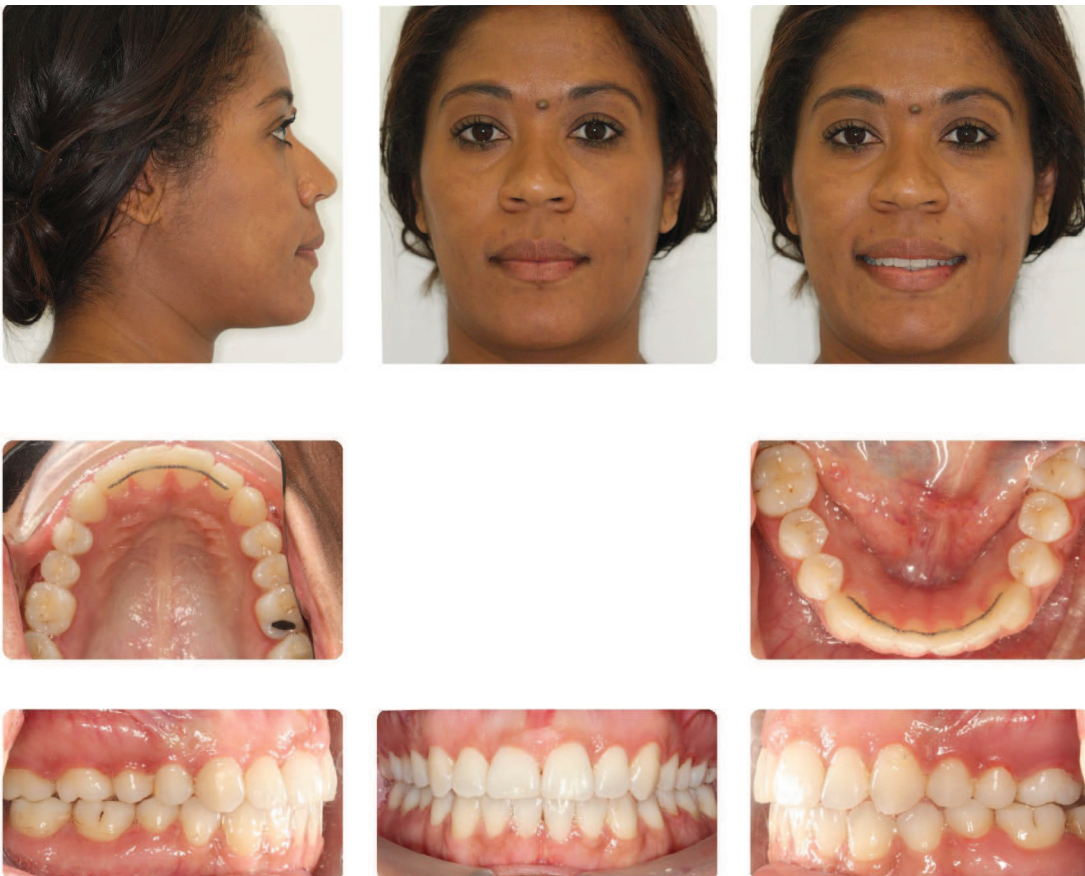

Figure 7



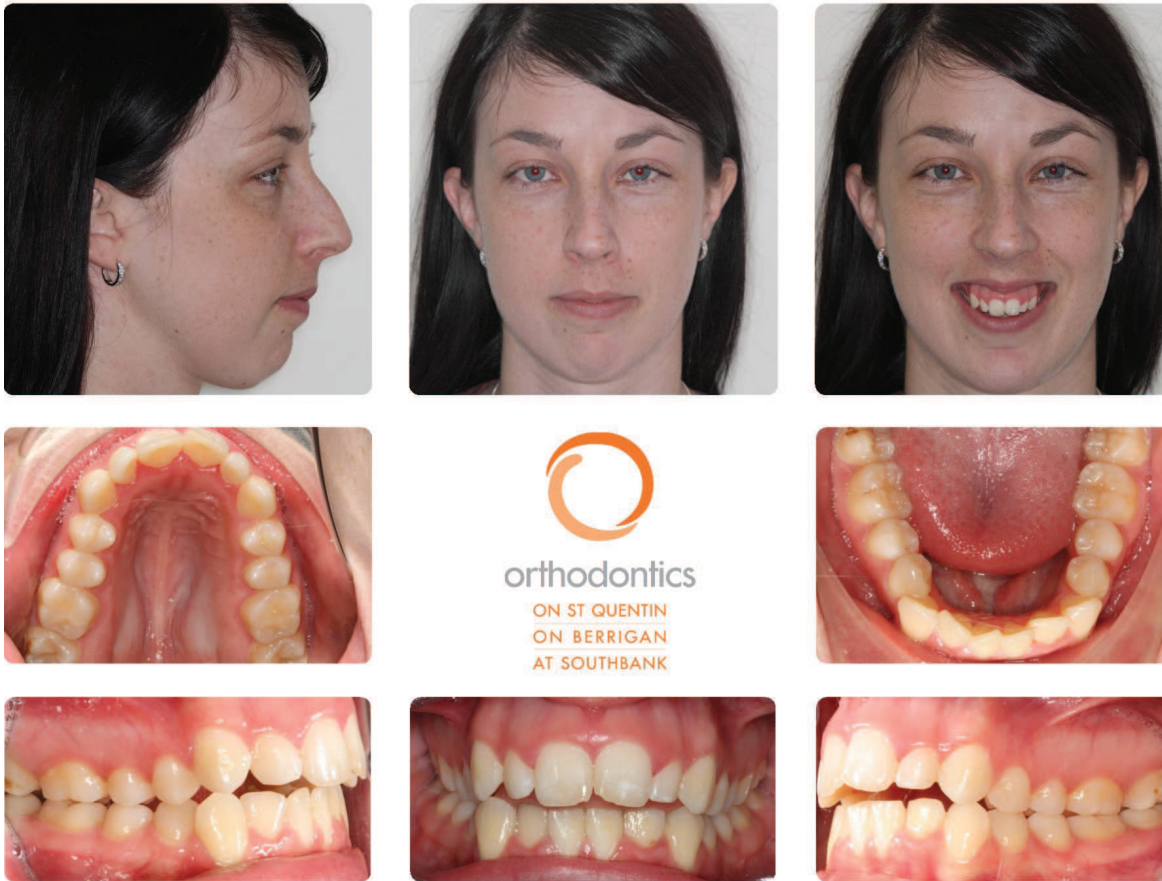

Figure 8

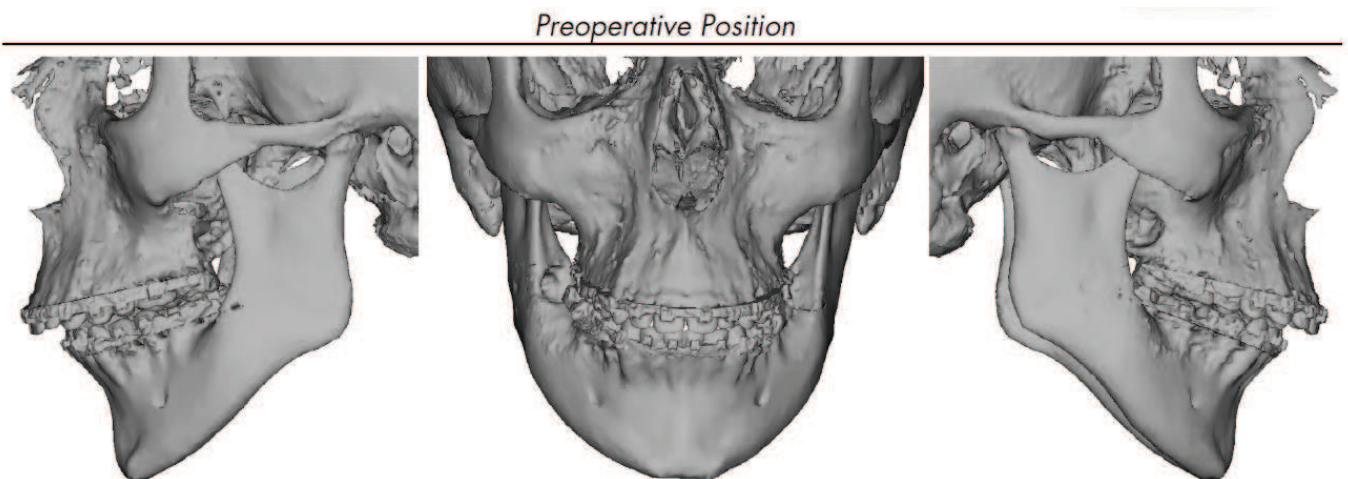


Figure 9

*Intermediate Position*

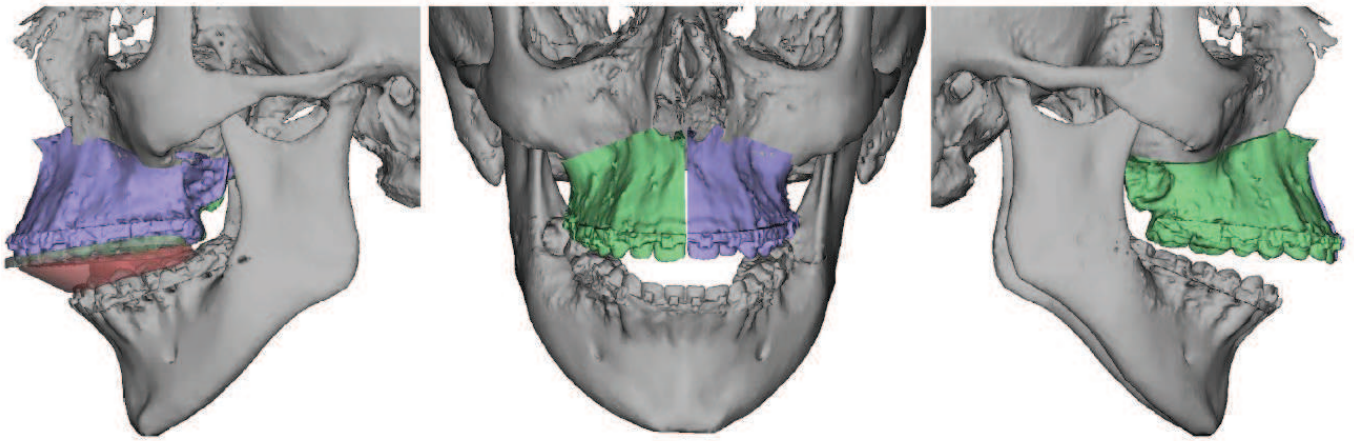


Figure 10

**Simulated Surgical Procedure:** Segmental LeFort I, BSSO, and Genioplasty

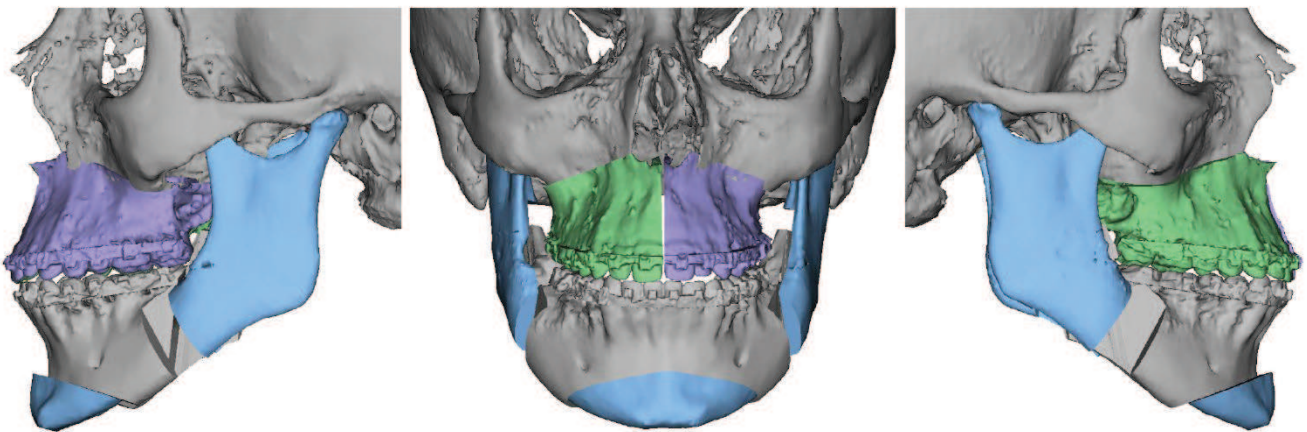


Figure 11

*Preoperative Position*

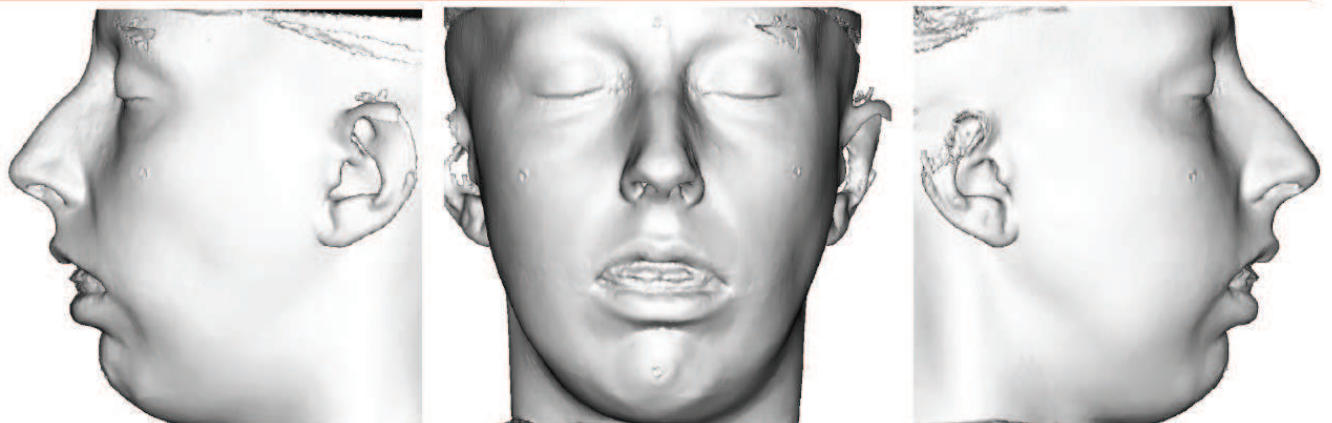

Figure 12



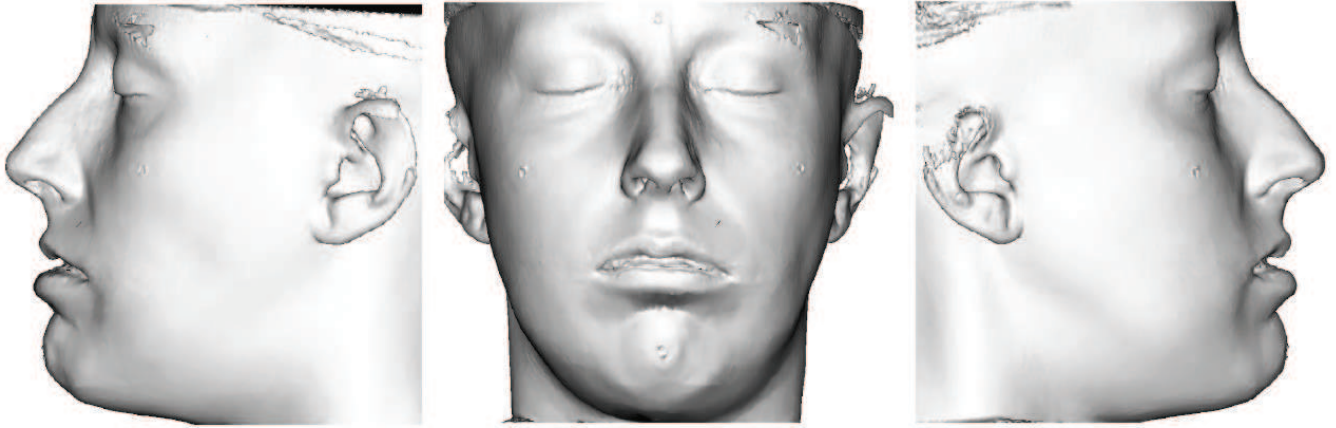

Figure 13

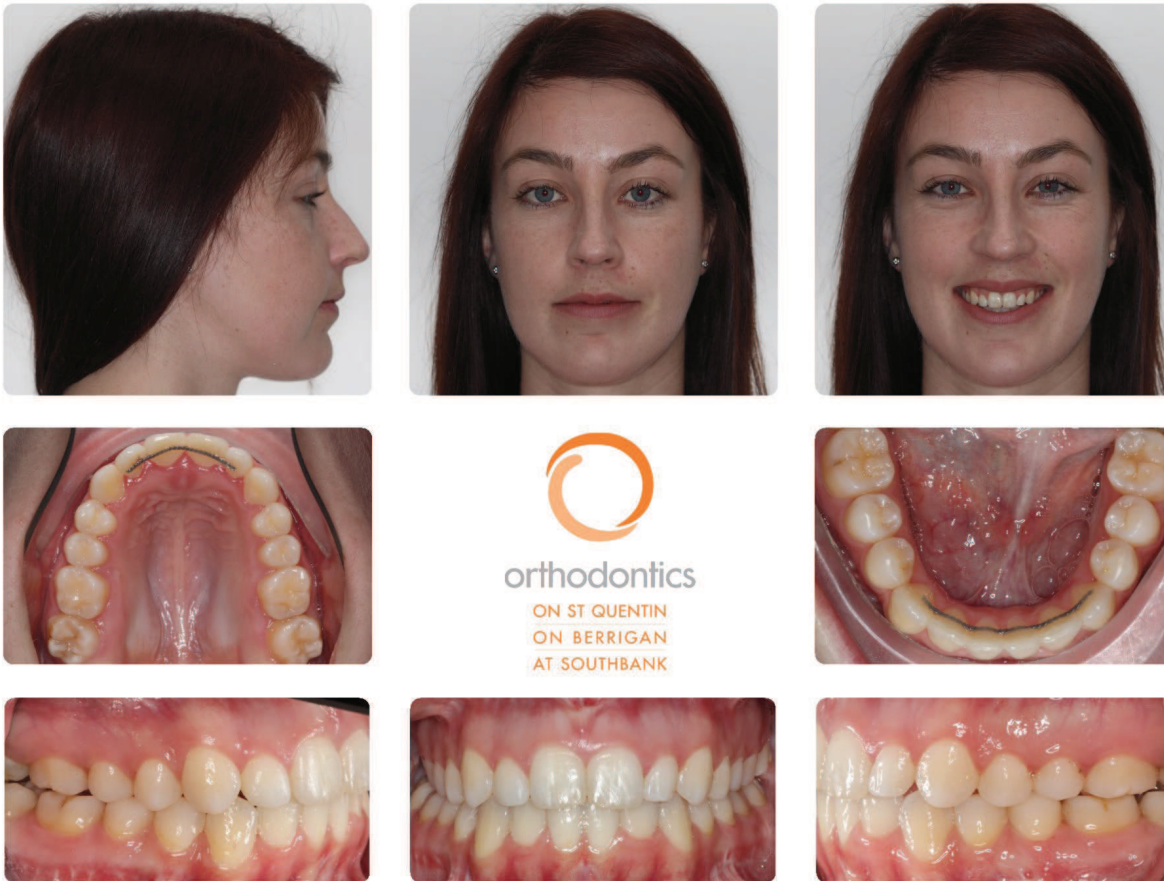

Figure 14